

## CAS CLINIQUE / CASE REPORT

### ACQUIRED NONMALIGNANT TRACHEOESOPHAGEAL FISTULA

<http://www.lebanesemedicaljournal.org/articles/59-3/case2.pdf>

Moussa ABI GHANEM<sup>1</sup>, Eid AZAR<sup>2</sup>, Bassam ABU KHALIL<sup>1</sup>

---

Abi Ghanem M, Azar E, Abu Khalil B. Acquired nonmalignant tracheoesophageal fistula. J Med Liban 2011 ; 59 (3) : 162-164.

---

**ABSTRACT :** Acquired nonmalignant tracheoesophageal fistula is a rare clinical entity and a difficult problem to diagnose and manage.

We report a 59-year-old woman diagnosed with a tracheoesophageal fistula secondary to prolonged intubation. The diagnosis was delayed for a year, hence her mild symptoms; cough and dysphagia mainly to liquids. These symptoms were thought to be side effects of her psychiatric medications especially that she had a buccal and lingual dyskinesia. She later had a trial of conservative treatment that failed and then she underwent surgical resection of the fistula and interposition of a muscle flap.

Acquired nonmalignant tracheoesophageal fistula is a preventable disease in intubated patient if some measures are taken, but even with the use of the newer endotracheal tubes (high-volume, low-pressure cuffs) this complication can still occur. The surgical treatment remains the best option.

#### INTRODUCTION

Tracheoesophageal fistula is defined as a pathological communication between the trachea and the esophagus. It is divided into congenital and acquired [1].

The most common fistulas are the congenital ones, with the diagnosis made early at a very young age [2]. The acquired ones are usually rare, divided into malignant and nonmalignant fistulas, occurring at any age. Acquired nonmalignant tracheoesophageal fistulas are secondary to infection, trauma, ruptured diverticulae, or prolonged intubation [3].

Once diagnosed, the tracheoesophageal fistula is best managed with surgery [1].

In this paper, we present a case of an acquired nonmalignant tracheoesophageal fistula, a rare complication post prolonged intubation requiring a very challenging clinical diagnosis and surgical management.

---

From the Departments of <sup>1</sup>Surgery, Cardiothoracic Surgery Division, <sup>2</sup>Medicine, Infectious Disease Division, St George Hospital University Medical Center, Beirut, Lebanon.

Correspondence to: Moussa Abi Ghanem, MD. Dept. of Cardiothoracic Surgery. St George Hospital UMC. P.O. Box 16 6378 - Beirut, Lebanon.

e-mail: [moussaabighanem@hotmail.com](mailto:moussaabighanem@hotmail.com)

---

Abi Ghanem M, Azar E, Abu Khalil B. La fistule trachéo-œsophagienne acquise d'origine non maligne. J Med Liban 2011 ; 59 (3) : 162-164.

---

**RÉSUMÉ :** La fistule trachéo-œsophagienne acquise d'origine non maligne est une entité clinique rare et un problème difficile à diagnostiquer et à gérer.

On présente le cas d'une patiente âgée de 59 ans atteinte d'une fistule trachéo-œsophagienne secondaire à une intubation prolongée. Le diagnostic a été retardé d'une année, à cause de ses symptômes minimes : toux et dysphagie surtout aux liquides. Ces symptômes ont été attribués aux effets secondaires de ses médicaments psychiatriques surtout qu'elle présentait une dyskinésie buccale et linguale. L'essai d'un traitement conservateur ayant échoué, elle a subi une résection chirurgicale de la fistule avec interposition d'un lambeau musculaire.

La fistule trachéo-œsophagienne acquise d'origine non maligne est une maladie évitable chez les patients intubés si quelques mesures préventives sont prises. Mais cette complication peut toujours se produire même avec l'utilisation des tubes endotrachéaux les plus récents (*high-volume, low-pressure cuffs*). Le traitement chirurgical reste la meilleure option.

#### CASE DESCRIPTION

A 59-year-old woman was admitted to our service with a history of dysphagia and cough for the past year.

The patient has a history of a bipolar disorder that is controlled with medications. One year ago, she was admitted to another hospital with an encephalopathy secondary to a change in her psychiatric medications. On admission, the patient was diagnosed having an aspiration pneumonia with mild hypoxemia that required intubation to protect her airways. She was admitted to the intensive care unit and remained intubated for a total of 10 days.

During those 10 days, the patient responded well to her medical treatment. The endotracheal tube was in good position and functioning well. She had no evidence of malnutrition and did not have any episodes of hypotension during that period.

The patient had an uneventful hospital course thereafter and was discharged home. She left the hospital with a buccal and lingual dyskinesia. Upon multiple clinic visits to her psychiatrist and neurologist, she continued to complain of this dyskinesia with a mild cough and dysphagia especially to liquids. All these symptoms were thought to be a side effect of her psychiatric medications.

She continued to have symptoms for a total of one year with no improvement. Other causes of her symptoms were considered and a water soluble contrast swallow (Figure 1) and a neck-chest CT scan with oral contrast were obtained. These studies showed a tracheoesophageal fistula approximately 2 cm above the sternal notch.

Conservative treatment (enteral feeding at first then nothing per os) was tried for two weeks without any success.

Surgical intervention was then discussed with the patient who agreed to proceed.

After induction of anesthesia and during surgery, the tip of the tracheal tube was kept below the fistula to avoid air leakage and gastric distention through the tracheal fistula while ventilating the patient. The tracheal tube was positioned with the aid of bronchoscopy and did not interfere with the fistula.

The surgical approach was done through an horizontal neck incision above the sternal notch. Dissection of the tissues was done meticulously in order to avoid injury to the recurrent laryngeal nerves. The tracheoesophageal fistula was found along the left latero-posterior side of the trachea at the level of the 6<sup>th</sup> ring. Resection of the fistula was then done and the tracheal and esophageal defects were closed in two layers of interrupted 4.0 vicryl for the trachea and 4.0 vicryl and 3.0 silk for the esophagus. At the end a pedicled strap muscle flap was interposed between the trachea and the esophagus with a 4.0 vicryl running suture. The patient was extubated right after the surgery and kept in the ICU for 24 hours.

She had an uneventful postoperative course thereafter. On postop day 5 she had a normal upper esophageal swallow and an oral diet was started with no problems. She did not receive any enteral or parenteral nutrition because her preoperative nutritional status was adequate. Upon resumption of diet, she was receiving a caloric intake of 30 kcal/kg with 15% protein per day. She was discharged home on postoperative day 7.

At six months post surgery she had a normal neck-chest CT scan and at one year she remains free of symptoms.

#### DISCUSSION

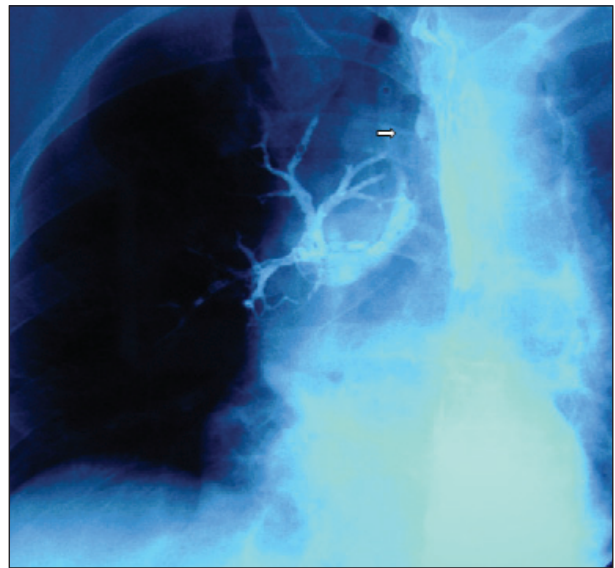
Tracheoesophageal fistula is a congenital or acquired pathological communication between the trachea and the esophagus [1].

Congenital anomalies are much more common than acquired ones, and are usually diagnosed immediately after birth or during infancy [2].

Acquired tracheoesophageal fistulas are quite rare, divided into malignant and nonmalignant fistulas and may occur in individuals of any age.

Acquired nonmalignant tracheoesophageal fistulas are secondary to infection, trauma, ruptured diverticulae, or prolonged mechanical ventilation with an endotracheal or a tracheostomy tube [3].

Out of all these factors, the preventable causes are



**FIGURE 1.** A water soluble contrast swallow showing a tracheoesophageal fistula (white arrow) with contrast in the tracheal bronchii.

avoiding prolonged intubation and trauma on intubation. Several measures are routinely done in the intensive care unit to avoid these complications.

In the past, high-pressure endotracheal tube cuffs were used, but these cuffs highly contributed to tracheal injury and have been replaced by high-volume, low-pressure cuffs. The intracuff pressure in the endotracheal or tracheostomy tubes should be always measured [4], and kept below 20 cm H<sub>2</sub>O. The cuff volume should be limited to between 6 and 8 ml [5]. Also, any inflation with a volume exceeding 10 ml should raise concerns about tracheal injury.

When the cuff pressure exceeds the tracheal mucosal perfusion pressure, several injuries can occur as in mucosal erosions, ulceration, stricture, tracheal stenosis, tracheomalacia and tracheoesophageal fistula [6-8].

Our patient had a high-volume, low-pressure cuff and the cuff volume was 6 cc. The intra-cuff pressure was only measured intermittently. Thus the cuff pressure may have been high and caused the injury because our patient did not have a traumatic intubation. That's why, tracheoesophageal fistula can occur even with the use of the newer endotracheal tubes with high-volume, low-pressure cuffs and even with close monitoring of the cuff pressure and volume.

Other factors that can cause decrease in mucosal blood flow to the tracheal tissue may contribute to the formation of the tracheoesophageal fistula. These include hypotension, hypoxemia, anemia, metabolic disorders, malnutrition, infection, sepsis, and steroid use.

Our patient had a pneumonia with mild hypoxemia but none of the other risk factors. She was also adequately sedated during mechanical ventilation.

The diagnosis of acquired nonmalignant tracheoesophageal fistula is usually made early, but in the case of our

patient, her symptoms were unrecognized for a year and mistaken for side effects of her psychiatric medications. Once the diagnosis of acquired nonmalignant fistula is confirmed, surgery is the treatment of choice. However, other options should be considered on a case per case basis.

Conservative treatment, keeping the patient with nothing per os is an option. In this case, conservative treatment was tried and failed. Stenting can be used for benign fistulas for a temporary period if the patient is critically ill and ventilated. This was not the case in our patient [9]. Endoscopic treatment has good results in the hands of experienced physicians in specialized centers. Through a bronchoscope, small fistulas can be closed using fibrin glue, small clips or argon plasma coagulation [10-12]. These options are definitely less invasive than surgery but couldn't be offered to our patient due to lack of expertise in this field of endoscopic intervention in Lebanon.

The decision regarding the best surgical approach depends on the size of the defect, location of the fistula and any associated tracheal damage.

For small fistulas with a normal trachea, surgical treatment consists of simple division of the fistula with primary closure of the esophageal and the tracheal defects through a collar incision. A strap muscle pedicle flap is then interposed between the trachea and the esophagus to reinforce the two suture lines [13-14]. The muscles used are either the sternohyoid or the sternothyroid.

For fistulas around the carina, a right lateral thoracotomy is a more appropriate approach with the use of the pleura or the intercostal muscles for the flap.

For larger defects with tracheal damage, the surgical repair requires tracheal resection and reconstruction. The esophageal defect should be closed in two layers, and a viable muscle flap interposed between the trachea and the esophagus [14].

In rare situations, esophageal diversion may be needed [15].

#### CONCLUSION

Acquired nonmalignant tracheoesophageal fistula is a rare entity. A traumatic intubation should be avoided and the endotracheal tube cuff pressures should be routinely measured and kept below 20 cm H<sub>2</sub>O and the cuff volume limited from 6 to 8 ml [16].

Once it occurs, the treatment of choice of the tracheoesophageal fistula remains surgical resection with interposition of a muscle flap.

#### REFERENCES

1. Singhal SK, Virk RS, Dass A, Sandhu BS. Tracheoesophageal fistula : New option in management. *Indian Journal of Otolaryngology and Head & Neck Surgery*. 2006 July ; 58 (3) : 300-2
2. Peison B, Levitzky E, Sprowls J. Tracheoesophageal fistula associated with tracheal atresia and malformation of the larynx. *Journal of Pediatric Surgery* 1970 Aug ; 5 (4) : 464-7.
3. Shah CP, Yeolekar ME, Pardiwala FK. Acquired tracheoesophageal fistula. *J Postgrad Med* 1994 ; 40 : 83-4.
4. Bishop MJ. Mechanisms of laryngotracheal injury following prolonged tracheal intubation. *Chest* 1989 ; 96 : 185-6.
5. Make BJ, Hill NS, Goldberg AI et al. Mechanical ventilation beyond the intensive care unit. Report of a consensus conference of the American College of Chest Physicians. *Chest* 1998 ; 113 : 289S-344S.
6. Windsor HM, Shanahan MX, Cherian K, Chang VP. Tracheal injury following prolonged intubation. *Aust N Z J Surg* 1976 Feb ; 46 (1) : 18-25.
7. Klainer AS, Turndorf H, Wu WH, Maewal H, Allender P. Surface alterations due to endotracheal intubation. *Am J Med* 1975 May ; 58 (5) : 674-83.
8. Flege JB Jr. Tracheoesophageal fistula caused by cuffed tracheostomy tube. *Ann Surg* 1967 Jul ; 166 (1) : 153-6.
9. Eleftheriadis E, Kotzampassi K. Temporary stenting of acquired benign tracheoesophageal fistulas in critically ill ventilated patients. *Surg Endosc* 2005 Jun ; 19 (6) : 811-15.
10. Scappaticci E, Ardissone F, Baldi S et al. Closure of an iatrogenic tracheoesophageal fistula with bronchoscopic gluing in a mechanically ventilated adult patient. *Ann Thorac Surg* 2004 Jan ; 77 (1) : 328-9.
11. Traina M, Curcio G, Tarantino I et al. New endoscopic over-the-scope clip system for closure of a chronic tracheoesophageal fistula. *Endoscopy* 2010 ; 42 (Suppl 2) : E54-E55.
12. Yankovic F, Castillo C, Saenz R, Navarrete C. Endoscopic argon plasma coagulation in recurrent tracheoesophageal fistula. Clinical series and review of the literature. *Gastroenterol Hepatol* 2009 Nov ; 32 (9) : 600-4. Epub 2009 Sep 8. Review.
13. Pisanu A, Reccia I, Nieddu R, Uccheddu A. Sternohyoid muscle flap interposition in the treatment of an acquired tracheoesophageal fistula. *Head Neck*. 2009 July ; 31 (7) : 962-7.
14. Reed MF, Mathisen DJ. Tracheoesophageal fistula. *Chest Surg Clin N Am* 2003 May ; 13 (2) : 271-89.
15. Mathisen DJ, Grillo HC, Wain JC, Hilgenberg AD. Management of acquired nonmalignant tracheoesophageal fistula. *Ann Thorac Surg* 1991 Oct ; 52 (4) : 759-65.
16. Hameed AA, Mohamed H, Al-Mansouri M. Acquired tracheoesophageal fistula due to high intracuff pressure. *Ann Thorac Med* 2008 ; 3 : 23-5.