

CAS CLINIQUE/CASE REPORT

PREOPERATIVE DIAGNOSIS OF RIGHT NONRECURRENT INFERIOR LARYNGEAL NERVE BY CT SCAN

Report of a Case and Review of the Literature

Bassam ABBOUD

Abboud B. Preoperative diagnosis of right nonrecurrent inferior laryngeal nerve by CT scan : Report of a case and review of the literature. *J Med Liban* 2007 ; 55 (1) : 46-49.

ABSTRACT • OBJECTIVE : The nonrecurrent inferior laryngeal nerve (NRILN) is a nerve anomaly that is associated with the developmentally aberrant subclavian artery. Thus, it is possible to predict NRILN by preoperative diagnosis of an aberrant subclavian artery. The purpose of this study was to report a new case of this anomaly and to assess the possibility of diagnosis of an aberrant subclavian artery preoperatively by CT scan of the neck, underline how such recognition is crucial for the prevention of intraoperative nerve damage and review the literature.

METHODS : We report a case of thyroid surgery associated with a right NRILN diagnosed preoperatively by CT scan of the neck.

RESULTS : The preoperative CT scan showed a retroesophageal aberrant right subclavian artery. The patient underwent total thyroidectomy for a multinodular goiter. She had identification of recurrent laryngeal nerve on the left side and NRILN on the right side. Postoperatively, the patient had normal vocal cord function on laryngoscopy.

CONCLUSION : It was possible to predict preoperatively a right NRILN by identifying an aberrant right subclavian artery on the CT film of the neck, which likely enabled the prevention of vocal cord paralysis.

INTRODUCTION

The major complication of thyroid surgery is hoarseness resulting from vocal cord paralysis. Identification and preservation of the recurrent inferior laryngeal nerve (RILN) during surgery is fundamental in preventing this complication [1-2].

The nonrecurrent inferior laryngeal nerve (NRILN), which goes into the larynx without recurring around the subclavian artery within the thoracic cavity, is a relatively rare anatomic variant without functional repercussions [1]. However, during cervicotomy this aberrant

Abboud B. Diagnostic préopératoire d'un nerf laryngé inférieur droit non récurrent par CT scan : A propos d'un cas et revue de la littérature. *J Med Liban* 2007 ; 55 (1) : 46-49.

RÉSUMÉ • OBJECTIF : Le nerf récurrent non récurrent (NRILN) est une anomalie nerveuse associée au développement d'une artère sous-clavière aberrante. Il est donc possible de prédire la présence de NRILN en préopératoire par le diagnostic d'une artère sous-clavière aberrante. Le but de ce travail est de rapporter un nouveau cas de cette anomalie suspectée par le CT scan préopératoire qui avait montré l'existence d'une artère sous-clavière aberrante et de passer en revue la littérature.

MÉTHODE : On rapporte un cas de chirurgie thyroïdienne associé à un NRILN droit suspecté en préopératoire par un CT scan du cou.

RÉSULTATS : Le CT scan préopératoire a mis en évidence une artère sous-clavière droite rétro-œsophagienne. La patiente a eu une thyroïdectomie bilatérale pour goitre multinodulaire. En per opératoire, on a identifié un nerf récurrent gauche et un NRILN à droite. En postopératoire, la malade avait une fonction normale des cordes vocales à la laryngoscopie.

CONCLUSION : Il est possible de prévoir en préopératoire la présence d'un NRILN droit par l'identification d'une artère sous-clavière droite aberrante sur un CT scan du cou. Ceci permet de prévenir la lésion du nerf en per opératoire et d'éviter la paralysie des cordes vocales.

nerve may become inadvertently damaged, causing permanent ipsilateral vocal cord paralysis. In most cases, NRILN is due to an aberrant development of the subclavian artery, the so-called a. lusoria [1-3]. This anomaly has been observed clinically [1-16] since Stedman first reported it in 1823. It is recommended that surgeons be aware of the possibility of an NRILN, when the RILN is not found in the periphery of the tracheoesophageal groove [7, 10-11], because the risk of injury in the presence of this anatomic variant is high, even for experienced surgeons [12].

For some authors [1, 3, 7, 12, 14, 17-18], CT scan or MRI of the neck, and ultrasound of the brachiocephalic artery obtained before surgery allow direct visualization of an aberrant right subclavian artery ; the identification of this anomaly variant should alert the radiologist and surgeon that a right NRILN is present, anticipating surgical technique, reducing the risk of neural injury.

The aim of this study was to report a new case of right

Department of General Surgery, Hôtel-Dieu de France Hospital, Faculty of Medicine, Saint-Joseph University, Beirut, Lebanon.

Correspondence : *Bassam Abboud M.D. Department of General Surgery. Hôtel-Dieu de France Hospital. Alfred Nac - cache Street. Beirut. Lebanon.*

Fax : +961 1 615295

E-mail : dbabboud@yahoo.fr

NRILN diagnosed preoperatively by direct visualization of an aberrant right subclavian artery in CT scan of the neck, underline how such recognition is crucial for the prevention of intraoperative nerve damage and review the literature.

CASE REPORT

A 75-year-old woman presented with the complaint of a right anterior neck mass, which was enlarging progressively, causing dyspnea and dysphagia. No family history of thyroid disease was noted. History didn't reveal any prior neck radiation.

Physical examination revealed a 5 cm right anterior neck painless and firm mass that moved with swallowing with substernal extension. Laboratory tests showed a normal serum thyroid hormones concentration. The thyroid ultrasound confirmed the diagnosis of a thyroid nodule of the right lower lobe measuring 5.5 cm of large diameter with substernal extension, and three thyroid nodules in the left lobe measuring 1.7 cm, 2.2 cm, and 2.7 cm respectively. The percutaneous fine-needle aspiration cytology was indeterminate. Preoperative CT scan of the neck and mediastinum showed a substernal goiter and retroesophageal aberrant right subclavian artery (Fig. 1).

Peroperatively, she had a left recurrent inferior laryngeal nerve in the tracheoesophageal groove with a right nonrecurrent inferior laryngeal nerve which ran transversally at the level of the thyroid isthmus (Fig. 2). She underwent total right hemithyroidectomy and near total left lobectomy by a cervical approach. Frozen section showed benign thyroid nodules. Postoperatively, she had a normal vocal function at laryngoscopy. The pathologic analysis showed the presence of multiple thyroid nodules without malignancy.

DISCUSSION

A systematic search for and careful dissection of the RILN during thyroidectomy is necessary to avoid surgical damage. The existence of anatomic variants in the course of the RILN is an additional reason for its systematic perioperative identification. One of the potential variants is NRILN; this variant originates from an aberrant embryologic origin of the subclavian artery [1-3]. The NRILN has been reported in 0.52% to 1.8% of cases making it a relatively rare anomaly [7, 19]. This anomaly was encountered only on the right side (except in the case of situs inversus). Although the NRILN is a rare occurrence, it results in dramatic consequences if damaged during thyroidectomy [7].

The NRILN can be explained by the course of RILN development during the embryologic stage. In the embryo, both the right and the left inferior laryngeal nerves supply the sixth branchial arches. With the descent of the heart, the nerves pass beneath the sixth aortic arch and ascend to the larynx. On the right side, the distal portion

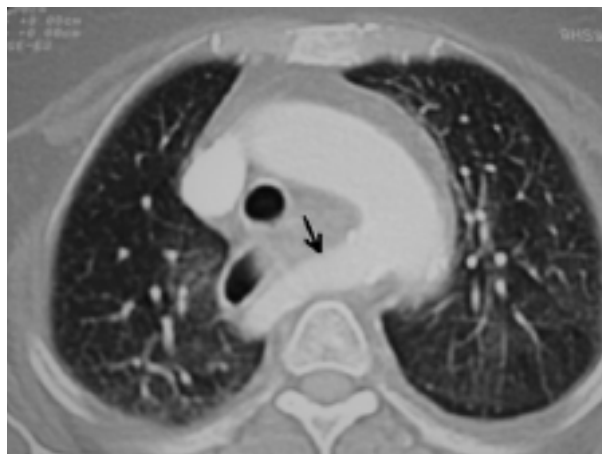

FIGURE 1
CT scan revealed a retroesophageal aberrant right subclavian artery.

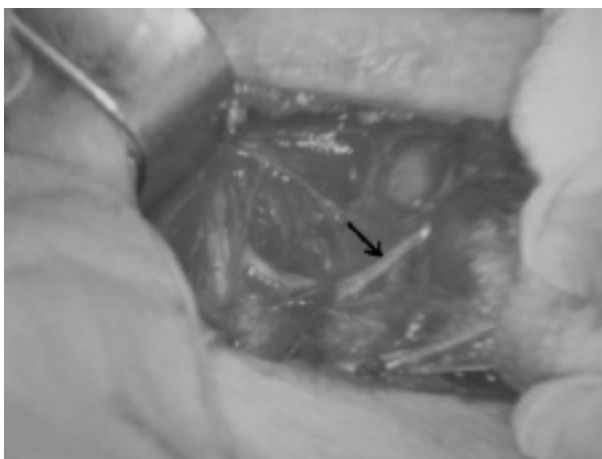


FIGURE 2
Peroperatively, right nonrecurrent inferior laryngeal nerve running transversally at the level of thyroid isthmus towards the larynx.

of the sixth aortic arch and the fifth aortic arch disappear, and the recurrent nerve moves up to lie beneath the fourth arch, which forms a portion of the subclavian artery. Occasionally, the right fourth aortic arch and proximal right dorsal aorta are obliterated, and the origin of the subclavian artery becomes anomalous. Its final origin is just below that of the left subclavian artery; it reaches the right side by crossing the midline behind the esophagus; very rarely, it may also cross the midline by passing between the trachea and the esophagus. Because the normal right subclavian artery is absent, the right RILN will move further cranially during elongation of the neck, passing more or less directly from the vagal nerve to the larynx. Three types of NRILN have been distinguished: in type IA, the nerve shows a straight course at the level of the upper thyroid pole; in type IB (the most common), the nerve runs transversally at the level of the thyroid isthmus; in type II, the nerve makes

a downwards curve, eventually reaching the lower pole of the thyroid gland [1, 3, 7].

No reliable clinical symptoms or signs indicate the possibility of NRILN preoperatively [2-3]. It is difficult to identify NRILN by preoperative imaging of any type [14]. An aberrant subclavian artery is almost always associated with the NRILN, however, so preoperatively identifying the aberrant subclavian artery would be tantamount to diagnosing the NRILN. In nearly all reports, the association of an aberrant subclavian artery and NRILN is confirmed after the detection of a NRILN during surgery, either by exploring the subclavian artery or by postoperative angiography [8, 10, 20]. Before operation, the diagnosis of the nervous anomaly may be made only if the corresponding vascular anomaly is suspected. Diagnosis of the aberrant subclavian artery has been based on • dysphagia lusoria on swallowing • an impression observed on the esophagogram from the left to the upper right of the esophagus [21] • an anomalous right subclavian artery origin observed at the right of the peak of the aorta arch on the anterior plain chest roentgenogram • an anomalous right subclavian artery traversing behind the esophagus and trachea or • by digital subtraction angiography [8] and/or magnetic resonance angiography findings [3]. Whether the dysphagia lusoria is actually the result of a thyroid tumor or an aberrant subclavian artery is hard to determine, however, and diagnosis from the plain chest roentgenogram has been reported in approximately 58% of cases. In one series [1], retrospective diagnosis was possible on a plain roentgenogram in only one case of the 6 cases treated. The CT scan diagnosis of an a. lusoria is firm, and is based on the direct identification of an aberrant vessel passing behind the esophagus. Many patients in some institutions have a CT or MRI study of the neck before thyroid surgery to evaluate the anatomic relationships between the thyroid gland and the surrounding structures [1, 12]. For some authors [18], identification of patients with nonrecurrent inferior laryngeal nerve was made by duplex ultrasound of the brachiocephalic artery. Thus, the presence of an a. lusoria can be reliably established without the need for an additional investigation [3]. Dorsal position of the subclavian artery virtually assures NRILN. This may enable prevention of vocal cord paralysis, the most frequent serious postoperative complication of thyroid surgery.

Because of its anatomic position, NRILN is not only at risk of being damaged during thyroidectomy but also during other surgical procedures such as neck dissection, parathyroidectomy, esophagectomy, and carotid endarterectomy [3, 22-23].

It is well known that even experienced surgeons may have difficulties retrieving the RILN [3, 24]. When performing cervicotomy, some authors [7] recommend that surgeons systematically and promptly locate the RILN as low in the neck as possible, but always below the trunk and branches of the inferior thyroid artery. If the recurrent nerve is not found at its usual place, the RILN should be sought more or less transversally between the

carotid artery and the larynx. It is relatively easy to check for the vascular underlying anomaly simply by noting the absence of the innominate artery. The throbbing from the aberrant artery can be felt in front of the vertebral plane by slipping the index finger along the edge of the esophagus [1].

The NRILN is a rare anomaly and can be suspected preoperatively from signs associated with the vascular anomaly such as dysphagia lusoria, thoracic X-ray imaging, and cervical ultrasound. If such signs are noted, a CT scan or MRI of the neck, and duplex ultrasound of the brachiocephalic artery are justified.

CONCLUSION

The nonrecurrence of the inferior laryngeal nerve always results from vascular anomaly during embryologic development of the aortic arches. It can be suspected preoperatively from signs associated with the vascular anomaly such as dysphagia lusoria and thoracic X-ray imaging. If such signs are noted, a CT scan or MRI of the neck, and duplex ultrasound of the brachiocephalic artery are justified. It was possible to predict preoperatively a right NRILN by identifying an aberrant right subclavian artery on the CT or MRI film of the neck. Nonrecurrence of the RILN is a rare anomaly but overlooking its possibility may lead to severe operative morbidity. This is an additional argument in favor of systematic dissection of RILN during thyroid or parathyroid surgery.

REFERENCES

1. Watanabe A, Kawabori S, Osanai H, Taniguchi M, Hosokawa M. Preoperative computed tomography diagnosis of nonrecurrent inferior laryngeal nerve. *Laryngoscope* 2001 ; 111 : 1756-9.
2. Defechereux T, Albert V, Alexandre J, Bonnet P, Hamoir E, Meurisse M. The inferior nonrecurrent laryngeal nerve : a major surgical risk during thyroidectomy. *Acta Chir Belg* 2000 ; 100 : 62-7.
3. Hermans R, Dewandel P, Debruyne F, Delaere PR. Arteria lusoria identified on preoperative CT and nonrecurrent inferior laryngeal nerve during thyroidectomy : A retrospective study. *Head Neck* 2003 ; 25 : 113-17.
4. Sanders G, Uyeda RY, Karlan MS. Nonrecurrent inferior laryngeal nerves and their association with a recurrent branch. *Am J Surg* 1983 ; 146 : 501-3.
5. Katz AD. Extralaryngeal division of the recurrent laryngeal nerve ; report on 400 patients and the 721 nerves measured. *Am J Surg* 1986 ; 152 : 407-10.
6. Friedman M, Toriumi D, Grybauskas V, Katz A. Nonrecurrent laryngeal nerves and their clinical significance. *Laryngoscope* 1986 ; 96 : 87-90.
7. Henry JF, Audiffret J, Denizot A, Plan M. The nonrecurrent inferior laryngeal nerve : review of 33 cases, including two on the left side. *Surgery* 1988 ; 104 : 977-84.
8. Campbell PR, Seprell JW, Young AE. Nonrecurrent inferior laryngeal nerves. The role of digital subtraction angiography to identify subjects. *Aust N Z Surg* 1991 ; 61 : 358-9.

9. Proye CAG, Carnaille BM, Goropoulos A. Nonrecurrent and recurrent inferior laryngeal nerve : a surgical pitfall in cervical exploration. Am J Surg 1991 ; 162 : 495-6.
10. Nagayama I, Okabe Y, Katoh H, Furukawa M. Importance of pre-operative recognition of the nonrecurrent laryngeal nerve. J Laryngol Oto 1994 ; 108 : 417-19.
11. Srinivassan V, Premachandra DJ. Nonrecurrent inferior laryngeal nerve : identification during thyroid surgery. ORL J Otorhinolaryngol Relat Spec 1997 ; 59 : 57-9.
12. Materazzi G, Berti P, Iacconi P, Miccoli P. Nonrecurrent laryngeal nerve predicted before thyroidectomy by pre-operative imaging. J Am Coll Surg 2000 ; 191 : 580.
13. Cannon CR. The anomaly of nonrecurrent laryngeal nerve : identification and management. Otolaryngol Head Neck Surg 1999 ; 120 : 769-71.
14. Toniato A, Pelizzo MR. Preoperative imaging of nonrecurrent laryngeal nerve. J Am Coll Surg 2001 ; 192 : 421-2.
15. Vallicioni J, Ndiaye M, Poissonnet G et al. Nonrecurrent inferior laryngeal nerve : review of 13 cases. Ann Otolaryngol Chir Cervicofac 2003 ; 120 : 268-70.
16. Sparta C, Cossu ML, Fais E et al. Nonrecurrent inferior laryngeal nerve : anatomy, frequency and surgical considerations. Minerva Chir 2004 ; 59 : 555-61.
17. Toniato A, Mazzarotto R, Piotto A, Bernante P, Pagetta C, Pelizzo MR. Identification of the nonrecurrent laryngeal nerve during thyroid surgery : 20-year experience. World J Surg 2004 ; 28 : 659-61.
18. Deveze A, Sebag F, Hubbard J, Jaunay M, Maweja S, Henry JF. Identification of patients with nonrecurrent inferior laryngeal nerve by duplex ultrasound of the brachiocephalic artery. Surg Radiol Anat 2003 ; 25 : 263-9.
19. Blondeau Ph, Neouze GL, Rene L. Le nerf laryngé inférieur non récurrent, danger de la chirurgie thyroïdienne. Ann Chir 1977 ; 31 : 917-23.
20. Avisse C, Marcus C, Delattre JF et al. Right nonrecurrent inferior laryngeal nerve and arteria lusoria : the diagnostic and therapeutic implications of anatomic anomaly. Review of 17 cases. Surg Radiol Anat 1998 ; 20 : 227-32.
21. Freed K, Low VHS. The aberrant subclavian artery. AJR 1997 ; 168 : 481-4.
22. Shimada T, Terashima H, Shimizu T, Abe R, Hirayama K. Esophageal carcinoma with nonrecurrent inferior laryngeal nerve. Ann Thorac Surg 2000 ; 70 : 1722-3.
23. Coody MA, Adler F, Davila JJ, Gahtan V. Nonrecurrent laryngeal nerve during carotid artery surgery : case report and literature review. J Vasc Surg 2000 ; 32 : 192-6.
24. Sturniolo G, D'Alia C, Tonante A, Gagliano E, Taranto F, Lo Schiavo MG. The recurrent laryngeal nerve related to thyroid surgery. Am J Surg 1999 ; 177 : 485-8.

التشخيص ما قبل العملية للعصب الحنجري السفلي الايمن الراجع (غير راجع) بواسطة المفرسة. سيرة حالة ومراجعة المنشورات

موجز : الموضوع – العصب الراجع (غير راجع) شذوذ عصبي يشترك مع وجود شريان تحت الترقوة شاذ، من الممكن اذا التكهّن بوجود عصب راجع (غير راجع) قبل العملية وذلك بتشخيص شريان تحت الترقوة شاذ. غاية هذه المقالة ذكر حالة جديدة لهذا الشذوذ المشتبه به بواسطة المفرسة قبل العملية والتي اظهرت وجود شريان تحت الترقوة شاذ، ومراجعة المنشورات.

الطريقة – نذكر حالة جراحة درقية مشتركة مع عصب راجع ايمن (غير راجع) اشتبه به قبل العملية بواسطة تفريسة العنق.

النتائج – اظهرت التفريسة قبل العملية شريان تحت الترقوة اليمنى وخلف المري. تم للمريضة استئصال الدرق بالجهتين لجدرة متعددة العقد. لوحظ قبل العملية العصب الراجع الايسر والراجع الايمن (غير راجع) وبعد العملية كانت وظيفة الحبال الصوتية طبيعية بتنظير الحنجرة.

الخلاصة – من الممكن التنبؤ قبل العملية بوجود العصب الايمن الراجع (غير راجع) اذا تبين وجود شريان شاذ بمفرسة العنق وهذا ما يسمح بتحاشي افة العصب اثناء العملية