

CAS CLINIQUE/CASE REPORT

GASTRIC INCARCERATION AND PERFORATION FOLLOWING POSTTRAUMATIC DIAPHRAGMATIC HERNIA

Case Report and Review of the Literature

Bassam ABBOUD¹, Georges TABET², Joe BOU JAOUDE³, Ghassan SLEILATY²

Abboud B, Tabet G, Bou Jaoude J, Sleilaty G. Gastric incarceration and perforation following posttraumatic diaphragmatic hernia : Case report and review of the literature. J Med Liban 2007 ; 55 (2) : 104-107.

ABSTRACT • OBJECTIVE : Herniation of abdominal contents through the diaphragm has been described in a variety of diaphragmatic defects and may occur secondary to diaphragmatic injury, either traumatic or iatrogenic. The aim of this study is to report a case of gastro-pleural fistula in a patient with traumatic diaphragmatic hernia.

CASE PRESENTATION : An 18-year-old male patient, with a past history of blunt abdominal trauma, presented with epigastric abdominal pain and dyspnea. A thoracoabdominal CT scan revealed the presence of a herniated portion of the stomach with suspected perforation and free fluid in the left hemithorax. An exploratory laparotomy was performed. The esophageal hiatus was normal but a 4 cm rent was discovered in the posterior leaf of the left hemidiaphragm. Passing through the defect was the fundus of the stomach with evidence of perforation in left pleural space causing empyema. Resection of the herniated portion of the stomach and running suture of the gastric body were performed. Diaphragm was directly repaired without graft. Finally, a chest tube was placed in the left hemithorax. Postoperative course was uneventful and he recovered without complications. He was discharged from hospital 13 days after surgery.

INTRODUCTION

Herniation of abdominal contents through the diaphragm has been described for a variety of diaphragmatic defects. The most common hernias are those occurring in the area of the esophageal hiatus. Following these in frequency are hernias occurring secondary to diaphragmatic injury, either traumatic or iatrogenic. Spontaneous

Abboud B, Tabet G, Bou Jaoude J, Sleilaty G. Incarcération et perforation gastrique dans une hernie diaphragmatique post-traumatique. Cas clinique et revue de la littérature. J Med Liban 2007 ; 55 (2) : 104-107.

RÉSUMÉ • BUT : Le passage du contenu abdominal à travers le diaphragme a été décrit pour une variété de défauts diaphragmatiques, traumatiques ou iatrogéniques. Le but de cet article était de rapporter un cas de fistule gastro-pleurale chez un patient ayant une hernie diaphragmatique traumatique.

PRÉSENTATION DU CAS : Un homme de 18 ans, ayant comme antécédent une histoire de traumatisme abdominal fermé, se présentait pour une douleur épigastrique avec dyspnée. Un CT scan thoraco-abdominal montrait la présence de liquide et d'une partie de l'estomac avec une suspicion de perforation dans l'hémithorax gauche. Une laparotomie exploratrice montrait un hiatus œsophagien normal et un orifice de 4 cm de diamètre dans la partie postérieure de l'hémidiaphragme gauche. A travers le trou, il y avait le fondus gastrique avec une fistule pleurale causant un empyème.

Une résection de la partie herniaire et nécrosée de l'estomac avec fermeture du corps gastrique ont été réalisées. Le défaut diaphragmatique a été suturé sans plaque. Un drain thoracique gauche a été placé en fin d'intervention. Les suites opératoires étaient simples. Le malade quitta l'hôpital à J13 postopératoire en bon état.

rupture of the diaphragm, though rare, is also possible [1-12].

The presence of diaphragmatic herniation in an adult is suggested by signs of gastrointestinal symptoms in the setting of a history of trauma and physical exam findings showing adventitious bowel sounds in the thorax. Chest pain, abdominal pain, respiratory distress, hemorrhages and peptic ulcers are common gastrointestinal manifestations [11].

With roentgenographic evidence of diaphragmatic herniation, surgery should be considered due to the grave nature of potential complications [11-12]. The sequelae of diaphragmatic hernia include intestinal obstruction, strangulation, gangrene and, eventually, perforation of gastro-intestinal tract [8-10, 13].

The aim of this study was to report a case of gastro-pleural fistula in a patient with traumatic diaphragmatic hernia with a review of the literature.

Departments of ¹General Surgery, ²Thoracic and Cardiovascular Surgery, ³Gastroenterology, Hôtel-Dieu de France Hospital, Faculty of Medicine, Saint-Joseph University, Beirut, Lebanon.

Reprint request : Bassam Abboud, MD. Department of General Surgery. Hôtel-Dieu de France Hospital. Alfred Naccache Street. Beirut-Lebanon.

Tel. : +961 1 615400 Fax : +961 1 615295
E-mail : dbabboud@yahoo.fr

CASE REPORT

The patient was a 18-year-old man, with a history of blunt abdominal trauma (car crash) three years ago and a history of recurrent symptoms of epigastric pain, appeared three months after the trauma, that resolved spontaneously. He was evaluated in the emergency department in August 2004 for a two days history of epigastric abdominal pain, nausea, weakness, dyspnea and shortness of breath.

When seen by the surgery team, the patient was afebrile and slightly tachycardic (108/mn) with a sinus rhythm and blood pressure of 100/60 mmHg. He was lethargic but oriented to persons, place and time. Physical exam revealed mild tenderness in the epigastric region, as well as decreased alveolar sounds in the left chest. The patient reported having had a bowel movement the morning of his initial presentation. Laboratory work demonstrated a white blood cell count of 13,100. The radiological findings included an elevated diaphragm bilaterally, more pronounced on the left side. Plain chest films demonstrated an obvious herniation of abdominal organs into the left thorax. A thoracoabdominal CT scan revealed the presence of free fluid in the thoracic cavity as well as a portion of the stomach with suspected perforation in the left hemithorax (Fig. 1). No other abnormality was noted in the abdomen.

The patient was scheduled for surgery. An exploratory laparotomy was performed. The abdomen was clear. The esophageal hiatus was normal but a 4 cm rent was discovered in the posterior leaf of the left hemidiaphragm. Passing through the defect was the fundus. The herniated portion of the stomach was strangulated with evidence of perforation in the left pleural space causing empyema. Resection of the herniated portion of the stomach and running suture of the gastric body were performed. Diaphragm was directly repaired without graft. Finally, a chest tube was placed in the left hemithorax. Postoperative course was uneventful. The patient required aggressive volume repletion. He was discharged from hospital 13 days after surgery.

DISCUSSION

Surgical findings in our case were compatible with traumatic injury of the diaphragm, that is, a 4 cm rent in the left hemidiaphragm. These findings were corroborated by the history of blunt abdominal trauma three years ago. In fact diaphragmatic rupture develops in nearly 5% of hospitalized automobile accident victims and 10% of victims of penetrating chest trauma [2]. It occurs most frequently on the left side [3], as in this case. Due to a higher intra-abdominal pressure, progressive herniation of abdominal contents may occur through the defect in the thorax [1, 11].

Delayed presentation of herniation following diaphragmatic rupture is not unusual. Traumatic injury to the diaphragm is often overlooked during the patient initial

presentation immediately following trauma and may not become evident until complications of herniation occur. Diaphragmatic injuries may be asymptomatic and remain undetected for days to years after injury, especially when they are small [4-6, 14-17]. Reber et al. [1] report 12%-60% of traumatic diaphragmatic injuries being missed during the initial hospital stay and diagnosis of herniation occurring as late as 28 years after the event. Contributing to these delays are insensitive diagnostic tests for diaphragmatic injury.

The presence of diaphragmatic herniation in an adult is suggested by signs of gastrointestinal symptoms, a history of trauma and physical exam findings such as adventitious bowel sounds in the thorax. Chest pain, abdominal pain, respiratory distress, hemorrhages and peptic ulcers are also common [11]. The sequelae of diaphragmatic hernia include intestinal obstruction, strangulation, gangrene and, eventually, perforation of the gastro-intestinal tract [8-10, 13]. Some diaphragmatic hernias may present later with pneumothorax or hydropneumothorax [14-16]. One case of nocturnal dyspnea secondary to a traumatic rupture of the diaphragm was reported [17].

Plain chest X-ray is often used as the initial approach for diagnosing a diaphragmatic injury in the acute setting. It is associated however with poor sensitivity. Chest roentgenograms are only 25% to 40.7% [2, 6] diagnostic for this type of injuries and only 31% of induced diaphragmatic defects are discovered prior to surgery [2]. Gas bubbles in the chest, visualization of the nasogastric tube above the hemidiaphragm, or irregularity of the diaphragm outline suggest diaphragmatic injury. Concurrent trauma related abnormalities such as hemothorax or pulmonary contusion can mimic or mask a diaphragmatic injury, especially with small tears and in the absence of herniation. CT scan [6, 18] allows bet-

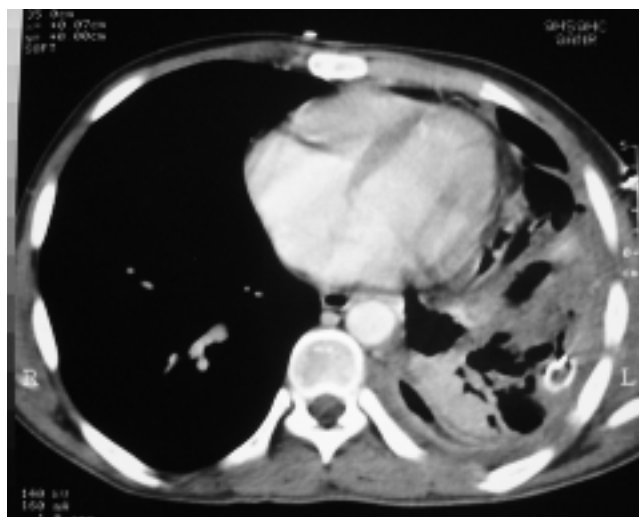


FIGURE 1

The thoracic CT scan revealed the presence of fluid and the gastric fundus in the left hemithorax.

ter visualization of the most subtle signs such as focal indentation of the liver, while evaluating coexisting thoraco-abdominal injuries. Despite systematic CT screening of thoracoabdominal injuries in hemodynamically stable patients and the description of multiple different CT signs, reported diagnostic sensitivities for blunt diaphragmatic rupture have been 42-90% [19-20]. In one series [19], multivariate logistic regression found six signs to be isolated good predictors ($p < 0.001$) of blunt diaphragmatic rupture : diaphragmatic discontinuity, segmental unrecognized diaphragm, intrathoracic herniation of abdominal content, elevated abdominal organs, thickened diaphragm, and the presence of both hemothorax and hemoperitoneum.

When a diaphragmatic injury is identified, prompt surgical intervention is warranted. The importance of early diagnosis lies in the fact that late presenting injuries are associated with significant morbidity and mortality. Abdominal viscera may herniate into the thoracic cavity, producing obstruction, strangulation, or pulmonary compromise. The serious nature of these complications mandates aggressive diagnostic evaluation of patients at risk for diaphragmatic injury [4, 6]. In acutely diagnosed injuries, laparotomy is the preferred approach because many of the patients have concurrent intra-abdominal injuries. In chronic cases, herniation of large sections of the abdominal contents may result in dense adhesions of the abdominal structures in the thorax. Most injuries can be repaired through a laparotomy incision ; but a thoracic approach may be necessary. Primary repair with interrupted non-absorbable mattress sutures is successful in the majority of cases. For large chronic defects, use of prosthetic materials such as Marlex and Prolene mesh may be necessary. Placement of an ipsilateral chest tube for drainage, and a nasogastric tube, is recommended for postoperative care [6]. Laparoscopy is an alternative approach to repairing acute traumatic diaphragmatic lacerations and chronic traumatic diaphragmatic hernias. Large traumatic diaphragmatic injuries adjacent to or including the esophageal hiatus are best approached via laparotomy [21-22].

CONCLUSION

Considering the difficulty in diagnosing injury to the diaphragm, surgeons, internists and emergency personnel should remain vigilant in their assessment of possible diaphragmatic hernias (high index of suspicion), especially in people who have a history of trauma. This case demonstrates the difficult nature of diagnosing a defect in the diaphragm. Repair of this patient's injury was delayed until a life-threatening complication confirmed the existence of diaphragmatic rupture. For this reason, roentgenographic evidence of diaphragmatic herniation should be considered as an indication for urgent surgical repair in order to prevent life-threatening potential complications.

REFERENCES

1. Reber PU, Schmeid B, Seiler CA, Baer HU, Patel AG, MW Buchler. Missed diaphragmatic injuries and their long-term sequelae. *Journal of Trauma* 1998 ; 44 : 183-8.
2. Meyers BF, McCabe CJ. Traumatic diaphragmatic hernia. Occult marker of serious injury. *Ann Surg* 1993 ; 218 ; 783-90.
3. Voeller GR, Reisser JR, Fabian TC, Kudsk K, Mangiante EC. Blunt diaphragmatic injuries : a five-year experience. *Am Surg* 1990 ; 56 : 28-31.
4. Saber WB, Moore EE, Hopeman AR, Aragon WE. Delayed presentation of traumatic diaphragmatic hernia. *J Emerg Med* 1986 ; 4 : 1-7.
5. Cozacov C, Krausz L, Freund U. Emergencies in delayed diaphragmatic herniation due to blunt trauma. *Injury* 1984 ; 15 : 370-1.
6. Kaw LL, Potenza BM, Coimbra R, Hoyt DB. Traumatic diaphragmatic hernia. *J Am Coll Surg* 2004 ; 198 : 668-9.
7. Prieto Nieto I, Perez Robledo JP, Rosalles Trelles V, De Miguel Ibanez R, Fernandez Prieto A, Calvo Celada A. Gastric incarceration and perforation following posttraumatic diaphragmatic hernia. *Acta Chir Belg* 2001 ; 101 : 81-3.
8. Chanson C, Hahnloser D, Nassiopoulos K, Petropoulos P. Gastric and omental incarceration through an occult traumatic diaphragmatic hernia in a scuba diver. *J Trauma* 2002 ; 52 : 146-8.
9. Leoncini G, Iuvilli L, Lupi P, Catrambone U. Intrathoracic perforation of the gastric fundus as a late complication of an unknown posttraumatic rupture of the diaphragm. *G Chir* 1998 ; 19 : 235-8.
10. Yamane Y, Kubo H, Ikeda M et al. Left diaphragmatic hernia due to blunt chest trauma complicated with intrapleural gastric perforation. *Kyobu Geka* 1995 ; 48 : 796-9.
11. Christiansen LA, Blichet-Toft M, Bertelsen S. Strangulated diaphragmatic hernia. A clinical study. *Am J Surg* 1975 ; 129 : 574-8.
12. Mansour KA. Strangulated traumatic diaphragmatic hernia : a case report. *Am Surg* 1974 ; 40 : 431-3.
13. Lerner CA, Dang H, Kutilek RA. Strangulated traumatic diaphragmatic hernia simulating a subphrenic abscess. *J Emerg Med* 1997 ; 15 : 849-53.
14. Hahn DM, Watson DC. Tension hydropneumothorax as delayed presentation of traumatic rupture of the diaphragm. *Eur J Cardiothorac Surg* 1990 ; 4 : 626-7.
15. De Jager CP, Trof RJ. Images in clinical medicine. Gastrothorax simulating acute tension pneumothorax. *N Engl J Med* 2004 ; 351 : e5.
16. Schwab RJ, Jarvik JG. Tension pneumothorax secondary to a gastropleural fistula in a traumatic diaphragmatic hernia. *Chest* 1991 ; 99 : 247-9.
17. Basso SM, Caratozzolo E, Massami M et al. Nocturnal dyspnea in a young adult male patient : a typical case of an unrecognized traumatic rupture of the diaphragm. *J Trauma* 2004 ; 56 : 720.
18. Caceres J, Mata JM, Castaner E, Villanaeva A. CT recognition of traumatic herniation of the stomach : the "sandwich sign". *J Thorac Imaging* 1995 ; 10 : 150-2.
19. Nchimi A, Szapiro D, Ghaye B et al. Helical CT of blunt diaphragmatic rupture. *AJR* 2005 ; 184 : 24-30.

20. Murray JG, Caoili E, Gruden JF, Evans SJ, Halvorsen RA Jr, Mackerise RC. Acute rupture of the diaphragm due to blunt trauma : diagnostic sensitivity and specificity of CT. AJR 1996 ; 166 : 1035-9.
21. Wadhwa A, Surendra JB, Sharma A et al. Laparoscopic

- repair of diaphragmatic hernias : experience of six cases. Asian J Surg 2005 ; 28 : 145-50.
22. Matthews BD, Bui H, Harold KL et al. Laparoscopic repair of traumatic diaphragmatic injuries. Surg Endosc 2003 ; 17 : 254-8.

انحباس المعدة وانتقابها بعد فتق رضي حجابي. سيرة حالة ومراجعة المنشورات.

موجز : الغاية – وصف مرور محتوى البطن خلال الحجاب في حالة عدة تشوهات حجابية رضية او علاجية. غاية هذه المقالة هي لسيرة حالة ناسور معدي جنبي عند مريض مصاب بفتق حجابي رضي.
الحالة – شاب عمره ١٨ عاماً في سوابقه سيرة رض بطني مغلق، راجع لألم شرسوفي مع ضيق نفس. اظهرت صورة المفروسة للصدر والبطن وجود سائل وقسم من المعدة مع اشتباه بوجود انتقاب فيها، بنصف الصدر الايسر. اظهرت بضع البطن الاستقصائي فوهة مريئية طبيعية وفوهة قطرها ٤ سنتمترات في القسم الخلفي لنصف الحجاب الايسر. ومن خلال الثقب يوجد قعر المعدة مع ناسور جنبي مسبب لقيح في الجنب. تحقق استئصال قسم الفتق النخر من المعدة مع اغلاق الجسم المعدي. خيط الشدوذ الحجابي بدون وضع صفيحة ثم وضع منزح (انبوب) صدري ايسر بنهاية العملية. كانت توالي العملية بسيطة وغادر المصاب المستشفى في اليوم الثالث عشر بعد العملية وبصحة جيدة.