

**ONE HUNDRED LIVER RESECTIONS : IMPROVED OUTCOME  
IN A TERTIARY CARE CENTER IN LEBANON**

Roger NOUN, Chadi SALLOUM, Smart ZEIDAN, Cyril TOHME, Bassam ABBOUD

---

Noun R, Salloum C, Zeidan S, Tohme C, Abboud B. One hundred liver resections : Improved outcome in a tertiary care center in Lebanon. *J Med Liban* 2007 ; 55 (2) : 63-69.

---

**ABSTRACT • BACKGROUND :** Recent reports highlight the reduced mortality and morbidity rates of liver resection in the last decades. The authors report on the surgical techniques and perioperative management that have yielded a low mortality and morbidity rates.

**METHODS :** One hundred consecutive liver resections carried out from 1997 to 2005 were reviewed. Data were collected retrospectively.

**RESULTS :** The indications for liver resection were malignant tumors in 73%. Major liver resection was performed in 52%. Overall, 42.5% of liver resections were performed without vascular clamping and 57% of liver resections were performed without blood transfusions. There was no intraoperative death and the overall mortality rate was 1%. The major complications rate was 28% and was related to the extent of resection. The mean length of hospital stay was 12 days.

**CONCLUSION :** The current series shows that with accurate preoperative evaluation, standardization of the surgical technique, appropriate use of vascular clamping method, and vigilant postoperative monitoring, an in-hospital mortality of 1% was achieved in a series where more than 50% of patients underwent a major hepatectomy.

INTRODUCTION

Liver resection is a major operation that has evolved from a rough, hasty, and bloody operation with a high operative risk to a refined, deliberate and relatively bloodless operation. Enhanced understanding of liver anatomy and function, technical advancement, vascular control, and improved patients selection and anesthetic management have all contributed to lowering the morbidity and mortality [1].

During the last decades, we have assisted to the cre-

---

Noun R, Salloum C, Zeidan S, Tohme C, Abboud B. Cent résections hépatiques : faible risque opératoire dans un centre de soins tertiaire au Liban. *J Med Liban* 2007 ; 55 (2) : 63-69.

---

**RÉSUMÉ • OBJECTIF :** L'analyse de récentes séries portant sur les résections hépatiques met en évidence une baisse certaine de la mortalité et de la morbidité au cours des dernières décennies. Les auteurs décrivent la technique chirurgicale et la prise en charge périopératoire qui ont contribué à la faible mortalité et morbidité de cette série.

**MÉTHODES :** Cent résections hépatiques consécutives réalisées de 1997 à 2005 ont été revues. Les données ont été recueillies rétrospectivement.

**RÉSULTATS :** Les indications étaient représentées par des tumeurs malignes dans 73%. Une résection hépatique majeure a été réalisée dans 52% des cas. Les résections ont été réalisées sans clampage dans 42,5% des cas et 57% des malades n'ont pas été transfusés. Le taux de mortalité a été de 1% et il n'y a pas eu de mortalité per opératoire. Le taux de complications a été de 28% et était corrélé à l'étendue de la résection. La durée d'hospitalisation moyenne était de 12 jours.

**CONCLUSION :** La présente série démontre que la conjonction d'une évaluation préopératoire précise, d'une standardisation de la technique opératoire, de l'utilisation de la technique appropriée de clampage, et d'une surveillance postopératoire rigoureuse, a abouti à une mortalité de 1% dans une série comportant plus de 50% de résections majeures.

ation of specialized liver surgery units all over the world. The routine practice of hepatic surgery in these referral centers has expanded the number of liver resections and led to the development of highly specific approaches to the liver while dropping the mortality to below 5% and the morbidity to less than 30% [2-4].

Our objective was to present a series of 100 consecutive liver resections. In this report, the surgical techniques, perioperative management and results are presented.

PATIENTS AND METHODS

Between 1997 and 2005, 100 consecutive elective liver resections were performed in the Department of Digestive Surgery at Hôtel-Dieu de France. All the procedures were carried out by one of us (RN) using a standard surgical technique. Data were collected retrospectively by two chief residents.

---

From the Department of Digestive Surgery, Hôtel-Dieu de France Hospital, Beirut, Lebanon.

Reprint address : Roger Noun, MD. Department of Digestive Surgery. Hôtel-Dieu de France Hospital. Bd. Alfred Naccache. POB 166830 Achrafieh. Beirut. Lebanon.

Fax : +961 1 615300 E-mail : rnoun@wise.net.lb

### Preoperative evaluation

All patients considered for resection underwent preoperative assessment. Exclusion criteria were as follows : ASA score 3, serum creatinine more than 120  $\mu\text{mol/L}$ , less than 8 weeks delay between systemic chemotherapy or chemoembolization and surgery, ascitis on ultra-sonography. In patients with hepatocellular carcinoma, non-tumorous liver biopsy assessing the presence or absence of chronic liver disease was performed preoperatively. In patients with chronic liver disease, only Child-Pugh score A patients were eligible for liver resection. In this group more than twice the normal upper range for ALT excluded major liver resection. In patients undergoing major liver resection, the volume of the remnant liver was estimated by volumetric helical computed tomography. When the volume of the remnant liver precluded a safe resection (less than 25% of the whole liver in patients with normal liver parenchyma or less than 40% in patients with abnormal liver parenchyma) portal vein occlusion of the hemiliver to be resected was performed.

### Anesthetic management

Prior to surgery, all patients had a pulmonary artery catheter, and a radial arterial line. Both intra-arterial pressure and central venous pressure were monitored continuously. Central venous pressure was maintained between 0 and 5 cm  $\text{H}_2\text{O}$  using a combination of anesthesia and early intraoperative fluid restriction. After the completion of parenchymal transection, and hemostasis, fluids and/or transfusions were administered in order to maintain urine output greater than 50 ml/h. The indications of preoperative blood transfusion were a decrease in hematocrit to 0.25 in patients without previous cardiac disease or to 0.30 in patients with previous cardiac disease, or hemodynamic instability. Intraoperative blood losses were estimated by removing the volume of the serum used in the operative field from the total volume into the suction canister. The use of vascular clamping, duration of warm ischemia and operative time were recorded.

### Surgical techniques

Surgery was performed through a bilateral subcostal incision with an upward midline extension or J-shaped incision. Thoracic extension was never needed. A midline incision was used for left lobectomy and tumorectomies. Abdominal exploration was performed to eliminate extrahepatic spread. For major resections (i.e., removal of three liver segments or more according to Couinaud's classification), cholecystectomy, if not already done, was performed [5]. The cystic duct was cannulated to detect bile leakage or to assess biliary patency after hepatectomy. The ipsilateral branch of the hepatic artery and portal vein were dissected at the liver hilum and divided oversewing the proximal portal vein. For left hepatectomy, the left portal branch was ligated and divided distal to the branches supplying the caudate lobe unless it had to be removed together with the left liver. The hepatic duct was ligated or sutured with the sur-

rounding glissonian sheath while exposed during parenchymal transection. Mobilization of the liver to be resected and extrahepatic control of the hepatic vein were carried out in the standard manner before proceeding to parenchymal transection [6]. For right hepatectomy, right lobectomy, extended left hepatectomy to segment 1 and caudate lobectomy, the paracaval portion of the caudate lobe was completely separated from the inferior vena cava by dividing many small hepatic veins. In patients with particularly large right liver tumors, which make right liver mobilization difficult and dangerous (hepatic vein avulsion, tumor rupture, prolonged ischemia), we used an anterior approach hepatectomy, i.e., parenchymal transection from the anterior surface of the liver down to the IVC without premobilization of the liver and extrahepatic control of the right hepatic vein [7-8]. The addition of the liver hanging maneuver as proposed by Belghiti et al. facilitates guidance, exposure and hemostasis at the deeper plane of parenchymal transection [9]. Parenchymal transection was begun without vascular clamping. When necessary, intermittent portal triad clamping was applied (repeated 15 min period of pedicular clamping followed by a 5 min period of reperfusion until the completion of the resection). For patients with involvement of the cavo-hepatic confluence, dissection in preparation for hepatic vascular exclusion was performed [10]. Parenchymal transection was performed using an ultrasonic dissector and Kelly clamp ; hemostasis and biliostasis were obtained with bipolar electrocautery and clips for small structures and with ligatures or sutures for large structures, only placed on the remaining cut surface of the liver. The transection was stopped temporarily and bimanual compression of the resection plane performed to achieve temporary hemostasis during the declamping period. The tumor free margin was examined repeatedly. Injection of methylene blue through the transcystic drain to detect bile leakage or air to assess biliary patency were performed and the drain was thereafter removed [11]. The falciform ligament was reconstructed for right hepatectomy or lobectomy to prevent torsion of the left hepatic vein. The cut surface of the liver was covered as best possible with the greater omentum. In all patients, a silicone rubber closed-suction drain was placed and the abdomen was closed with continuous sutures.

### Postoperative care

After surgery, patients, particularly those with major hepatectomy and/or cirrhosis and those with associated procedure were monitored in the intensive care units and were returned to the wards at the discretion of the intensivist. Postoperative parameters of hepatocyte damage and recovery including serum transaminases levels, serum bilirubin level and prothrombin time were monitored until the day of discharge. Routine abdominal ultrasound was carried out at between days 3 and 6 or in any patient with a suspected infected collection. All fluid collections were drained percutaneously with bacteriologic cultures.

**TABLE I**  
TYPES OF PROCEDURES  
IN 100 CONSECUTIVE LIVER RESECTIONS

HEPATECTOMY	N
<b>MAJOR HEPATECTOMY</b>	
■ Right hepatectomy	23
■ Extended right hepatectomy to segment 4	10
to segment 1	2
■ Left hepatectomy	8
■ Extended left hepatectomy to segment 5-8	2
to segment 1	6
■ Segmentectomy 4-5-6	1
<b>MINOR HEPATECTOMY</b>	
■ Left lobectomy	13
■ Bisegmentectomy segments 4-5	8
segments 5-6	5
segments 6-7	3
■ Segmentectomy	9
■ Tumorectomy	10

### Endpoints

The main assessed endpoints were the global in-hospital mortality and morbidity rates ; the need of vascular clamping, its type and duration ; the units of blood transfused ; the incidence, nature and number of postoperative complications ; and the length of hospital stay. Pulmonary complications included all clinically symptomatic pleural effusion, atelectasis or infection necessitating specific treatment. Liver failure was defined by a prothrombine time of less than 50% of normal, and/or by serum bilirubin more than 50  $\mu\text{mol/L}$  on postoperative day 5 or thereafter. Data are expressed as mean  $\pm$  SD. Comparisons between groups were analyzed by Student's t test. Significance was defined as  $p < 0.05$ .

**TABLE II**  
INTRAOPERATIVE DATA  
ACCORDING TO THE TYPE OF LIVER RESECTION

	MAJOR (n = 52)	MINOR (n = 48)
Intraoperative blood losses (ml)	989 $\pm$ 1250	620 $\pm$ 834
[Range]	[100-5000]	[200-920]
Patients without transfusions (%)	18 (34.5)	39 (81)*
Ischemia duration (minutes)	30 $\pm$ 9	18 $\pm$ 12
[Range]	[17-70]	[12-44]
Patients without clamping (%)	6 (12)	35 (73)*
Operative time (minutes)	392 $\pm$ 209	140 $\pm$ 106*
[Range]	[135-640]	[90-345]

\*  $p < 0.05$

## RESULTS

### Population characteristics

There were 51 males and 44 females with a mean age of 56 years (17-82). The indications for liver resection were malignant tumors in 73 (41 secondary malignancies, 12 hepatocellular carcinomas, 8 Klatskin tumors, 7 gallbladder carcinomas, 5 intrahepatic cholangiocarcinomas) and benign disease in 27 (10 hydatid cysts, 4 adenomas, 4 Caroli's disease, 3 angiomas, 2 focal nodular hyperplasias, 2 benign biliary strictures, 1 inflammatory pseudo-tumor, 1 intrahepatic bile duct stones). Five patients with bilobar liver colorectal metastasis underwent two-staged hepatectomies and portal vein branch ligation of the hemiliver to be resected.

### Intraoperative course

Major liver resection represented 52% of all resections (Table I). Twenty-four associated abdominal procedures were performed at the same time of resection and included 14 Roux-en-Y biliary reconstructions, 3 common bile duct explorations, 3 pericystectomies, 1 colectomy, 1 ileostomy closure, 1 splenectomy and 1 gastrectomy. Parenchymal transection was started without vascular clamping. Intermittent portal triad clamping was then applied as needed. Vascular clamping was necessary in 46 (88%) of major liver resections and in 13 (27%) of minor liver resections ( $p < 0.05$ ). The mean duration of vascular clamping was longer and estimated blood losses were higher for major resection without statistical significance. Blood transfusions was necessary in 65% of major resections and in 20.5% of minor resections ( $p < 0.05$ ) (Table II). In addition, 67% of the patients who received blood transfusions received only 1 to 2 U of blood (Table III). Operative time were significantly shorter for minor resections ( $p < 0.05$ ). Anterior approach right lobectomy supplemented with liver hanging was performed in two patients with huge right lobe tumors (Fig. 1). In two patients with involvement of the vena cava, in whom dissection in preparation for hepatic vascular exclusion was performed, the resection could have been achieved without the need for hepatic vascular exclusion (Fig. 2 and Fig. 3). Portal vein resection and primary repair was performed in a patient with Klatskin tumor undergoing an extended left hepatectomy. Minimal intraoperative air embolism, detected by intraoperative capnography, occurred in one patient during parenchymal transection.

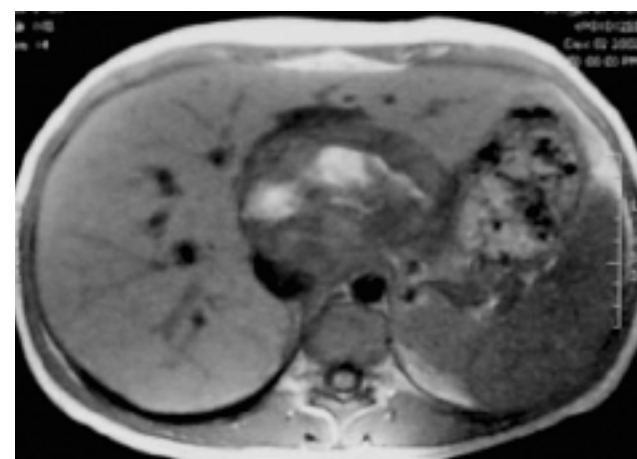
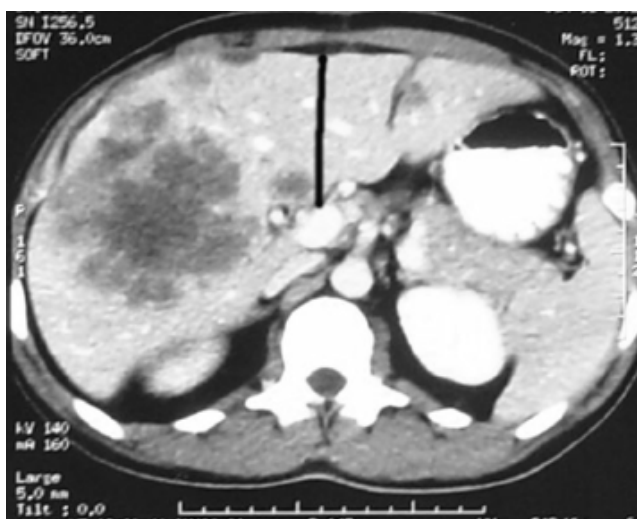### Postoperative course

One death related to toxic epidermal necrolyse (Lyell's syndrome) occurred accounting for in-hospital mortality of 1% and the major complication rate was 28%. The major complications are listed in table IV and their incidences were related to the extent of resection. One patient necessitated reoperation for persistent hemorrhage. The mean length of hospital stay was 12 days (range, 5-35).

**TABLE III**  
NUMBER OF PATIENTS AND EXTENT OF TRANSFUSION BY TYPE OF RESECTION

PROCEDURE	NUMBER OF PATIENTS				
	Total	Units of Packed RBC			
		0	1-2	3-5	> 6
Right hepatectomy	23	7	11	4	1
Extended right hepatectomy	11	3	3	3	2
Left hepatectomy	8	6	2	0	0
Extended left hepatectomy	8	2	4	2	0
4-5-6	1	1	0	0	0
2-3	13	11	2	0	0
4-5	8	5	2	1	0
5-6	5	4	1	0	0
6-7	3	1	1	1	0
Unisegmentectomy	9	7	2	0	0
Tumorectomy	11	11	0	0	0

RBC : red blood cells

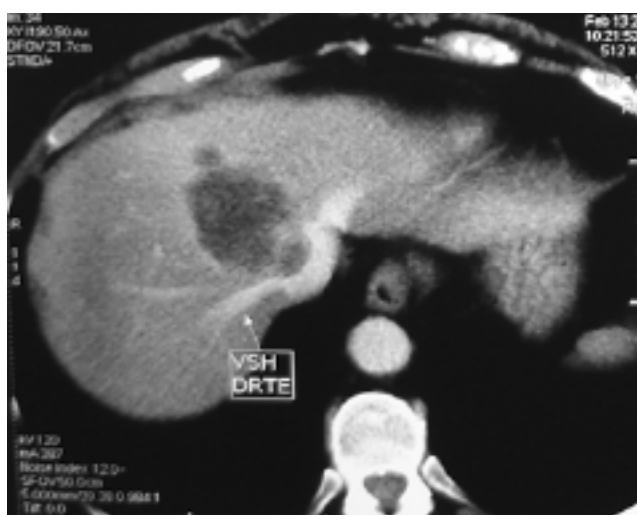

1

2

**FIGURE 1**  
*Computed tomography scan showing the direction and line of parenchymal transection in the anterior approach for a large colorectal metastasis.*

**FIGURE 2**  
*Computed tomography scan shows a liver metastasis from a colorectal carcinoma that infiltrates the right and middle hepatic veins with major compression of the supra-hepatic vena cava. Vessels dissection in preparation for hepatic vascular exclusion as a safe approach was performed at the beginning of the procedure. Involvement of the vena cava was less than expected by imaging studies and liver resection was achieved under intermittent portal triad clamping.*



3

**Figure 3**  
*Computed tomography scan shows major involvement of the retro-hepatic vena cava by a voluminous adenoma of segment 1. Vessels dissection in preparation for hepatic vascular exclusion as a safe approach was performed at the beginning of the procedure. However, liver resection was achieved under intermittent portal triad clamping.*

**TABLE IV**  
MAJOR COMPLICATIONS ASSOCIATED  
WITH 100 CONSECUTIVE LIVER RESECTIONS

COMPLICATIONS	Major Resections No.	Minor Resections No.
Air embolism	1	0
Pulmonary complications	10	3
Subphrenic collections	5	1
Biliary fistula	3	0
Hemorrhage	1	0
Ascitis	2	0
Portal vein thrombosis	1	0
Liver failure	1	0
<b>Total</b>	<b>24</b>	<b>4</b>

### DISCUSSION

Liver resection has historically been associated with intraoperative death and regarded as a difficult and dangerous procedure. Adequate liver surgery training was difficult to obtain and most surgical trainees were exposed only to hepatic trauma and damage control scenarios.

In the mid 1980s the emergence of hepatobiliary surgery as a distinct specialty resulted in the development of high-volume units and specialized surgeons [12]. The routine practice of hepatic surgery in these specialized units has led to the development of highly specific approaches to the liver while dropping the mortality to below 5% and the morbidity to less than 30% [9, 13].

The in-hospital mortality and morbidity rates in the current series are comparable to other reported series during the same period [9, 12-15]. In addition, intraoperative death, which was the major risk of liver resection was not observed in the current study, although major hepatectomies were performed in more than 50% of the patients. This experience which is shared by other specialized units is the result of accurate patients selection, preoperative evaluation and preparation, standardization of the surgical technique, appropriate use of vascular clamping method, and postoperative monitoring (Table V).

The liver parenchyma is an important preoperative consideration. In patients with chronic liver disease, only patients with fibrosis or Child-Pugh score A cirrhosis were eligible for liver resection. In the latter group, more than twice the normal upper range for ALT excluded major liver resection as previously reported [16-17]. Patients with Klatskin's tumors and major cholestasis underwent preoperative percutaneous biliary drainage of the future remnant liver until serum bilirubin values were below 50 µmol/l as recommended by Nimura [18]. In patients with preoperative chemotherapy, an interval of 8 weeks was observed between the end of chemotherapy and resection [19].

The remnant liver volume is another important preoperative consideration. The exact minimal hepatic volume required to avoid postoperative liver failure and complications is still unknown and the indications of portal vein embolization remains arbitrary. Usually, portal vein embolization is performed when the anticipated remnant volume is less than 25% of the whole liver in patients with normal liver parenchyma or less than 40% in patients with abnormal liver parenchyma. In this series, we used portal vein branch ligation rather than embolization in 5 patients with bilobar liver colorectal metastasis with planned two-step surgery [20]. In the first step, colorectal resection was associated with clearance of metastasis of the future remnant liver (with minor involvement) and with portal vein branch ligation of the hemiliver that will be resected (with major involvement) in the second step. The rationale for this strategy was to avoid the attendant risks of combined major liver resection with colorectal resection, to avoid progression of metastasis of the future remnant liver that might be induced by portal vein ligation and contralateral hypertrophy, and to obtain adequate volume of the future remnant liver. However, an adequate liver volume is not an absolute safeguard against postoperative liver failure, because intraoperative massive bleeding, compressive or ischemic injury to the liver remnant can precipitate postoperative liver failure.

The surgical technique presented here focuses on limiting blood losses, which has been shown to be the main decisive factor in determining the short-term prognosis

**TABLE V**  
PERIOPERATIVE RECOMMENDATIONS  
FOR GOOD RESULT

#### PREOPERATIVE

- Evaluation of underlying parenchyma
- Evaluation of volume of future remnant liver
- Percutaneous drainage of cholestatic liver

#### INTRAOPERATIVE

- Adequate exposure through generous incision
- Extrahepatic control of hepatic veins
- Avoidance of dissection of hepatic duct during hilar dissection
- Intermittent portal triad clamping supplemented with low central venous pressure
- Prompt hemostasis to reduce ischemic period
- Avoidance of prolonged or forceful liver rotation
- Checking for and suture of bile leakage and bleeding sites

#### POSTOPERATIVE

- Vigilant monitoring of parameters of hepatocyte damage and recovery
- Avoidance of overloading the circulation
- Early oral nutrition
- Routine abdominal Doppler ultrasounds and chest X-ray

of patients undergoing liver resection, and on limiting ischemic injury to the liver remnant. Blood losses and ischemia time are proportional to the transection surface area. Establishing a technique to transect the liver with ultrasonic dissector without clamping and using vascular clamping as needed during the progress of the parenchymal transection is therefore critical especially when a large transection area is involved. This policy of vascular clamping on a as needed basis resulted in that 42.5% of our liver resections were performed without clamping and that durations of our ischemia time, when vascular clamping was used, were reduced as compared with other reported series [10, 22]. However, a longer operation time was required.

When clamping was necessary, we favored, like others, intermittent portal clamping supplemented with low central venous pressure anesthesia [21-22]. This clamping method provides the ability to increase the overall duration of clamping, enables the surgeon to perform parenchymal transection without haste, allows the surgeon to relax and to assess the resection margins during the periods of unclamping, and provides evidence of superiority in terms of parenchymal tolerance to ischemia especially in the presence of abnormal parenchyma. If backflow bleeding occurs during intermittent portal triad clamping or when anesthetic techniques fail to lower the central venous pressure, infrahepatic caval clamping can be combined with minor hemodynamic consequences [23]. Cautious application of vascular clamping reduced blood losses and more than half of the patients of the current series did not require blood transfusion. Although hepatic vascular exclusion was previously recommended for tumor involving the cavo-hepatic intersection, we find like others that liver resection can be performed without total vascular exclusion even for tumors of the paracaval region. Usually caval infiltration is less than expected by imaging studies and this method of vascular clamping should be restricted to exceptional patients with major involvement of the vena cava that demands substitution of the involved vessel [10, 24]. Conversely, dissection in preparation for hepatic vascular exclusion can be used as a safe approach technique when the tumors are near the hepatic vein-vena cava confluence [23].

In conclusion, with technical refinements, use of adequate vascular clamping method and perioperative care we achieved an in-hospital mortality of 1% in a series where more than 50% of patients underwent a major hepatectomy. In addition, attention in every patient to fine details at each step of the procedure reduced the incidence of bile leakage, postoperative hemorrhage and subphrenic abscess [25]. The knowledge of the natural history of hepatectomy and vigilant postoperative monitoring allowed early detection and prompt treatment of postoperative complications [26].

## REFERENCES

1. Iwatsuki S, Starzl TE. Personal experience with 411 hepatic resections. *Ann Surg* 1988 ; 208 : 421-34.
2. Strong RW, Lynch SV, Wall DR, Ong TH. The safety of elective liver resection in a special unit. *Aust N Z Surg* 1994 ; 64 : 530-4.
3. Choti MA, Bowman HM, Pitt HA et al. Should hepatic resections be performed at high-volume referral centers ? *J Gastrointest Surg* 1998 ; 2 : 11-20.
4. Belghiti J, Hiramitsu K, Benoit S, Massault PP, Sauvanet A, Farges O. Seven hundred forty-seven hepatectomies in the 1990s : An update to evaluate the actual risk of liver resection. *J Am Coll Surg* 2000 ; 191 : 38-46.
5. Couinaud C. Schéma général de la distribution intrahépatique. In : Couinaud C, editor. *Le Foie : Etudes anatomiques et chirurgicales*. Paris, France : Masson & Cie, 1957 : 9-12.
6. Farges O, Noun R, Belghiti J. Vascular occlusion techniques for liver resections. *Ann Ital Chir* 1997 ; 68 : 767-73.
7. Lai E, Fan ST, Lo CM, Chu KM, Liu CL. Anterior approach for difficult major right hepatectomy. *World J Surg* 1996 ; 20 : 314-18.
8. Liu CL, Fan ST, Lo CM, Poon RTP, Wong J. Anterior approach for major right hepatic resection for large hepatocellular carcinoma. *Ann Surg* 2000 ; 232 : 25-31.
9. Belghiti J, Guevara OA, Noun R, Saldinger PF, Kianmanesh R. Liver hanging maneuver : A safe approach to right hepatectomy without liver mobilization. *J Am Coll Surg* 2001 ; 193 : 109-11.
10. Belghiti J, Noun R, Zante E, Ballet T, Sauvanet A. Portal triad clamping or hepatic vascular exclusion for major liver resection. A controlled study. *Ann Surg* 1996 ; 224 : 155-61.
11. Noun R, Singlant JD, Belghiti J. A practical method for quick assessment of bile duct patency during hepatic resection. *J Am Coll Surg* 1996 ; 183 : 77-8.
12. Koea J. Getting started as a hepatobiliary surgeon : lessons learned from the first 100 hepatectomies as a consultant. *N Z Med J* 2005 ; 118 : U1330.
13. Metreveli RE, Sahm K, Dentsman F, Abdel-Misih R, Petrelli NJ. Hepatic resection at a major community-based teaching hospital can result in good outcome. *Ann Surg Oncol* 2005 ; 12 : 133-7.
14. Khatri VP, Petrelli NJ, Belghiti J. Extending the frontiers of surgical therapy for hepatic colorectal metastases : is there a limit ? *J Clin Oncol* 2005 ; 20 : 8286-8.
15. Janargin WR, Gonen M, Fong Y et al. Improvement in perioperative outcome after hepatic resection : analysis of 1803 consecutive cases over the past decade. *Ann Surg* 2002 ; 236 : 397-406.
16. Noun R, Jagot P, Farges O et al. High preoperative serum alanine transferase levels : effect on the risk of liver resection in Child grade A cirrhotic patients. *World J Surg* 1997 ; 21 : 390-4.
17. Farges O, Malassagne B, Flejou JF et al. Risk of major liver resection in patients with underlying chronic liver disease. A reappraisal. *Ann Surg* 1999 ; 229 : 210-15.
18. Nagino M, Kamiya J, Arai T, Nishio H, Ebata T, Nimura Y. Anatomic right trisectionectomy with caudate lobectomy for hilar cholangiocarcinoma. *Ann Surg* 2006 ; 243 : 28-32.
19. Farges O, Belghiti J, Kianmanesh R et al. Portal vein

- embolization before right hepatectomy : prospective clinical trial. Ann Surg 2003 ; 237 : 208-17.
20. Kianmanesh R, Farges O, Abdalla E, Sauvanet A, Ruszniewski P, Belghiti J. Right portal vein ligation : A new planned two-step all-surgical approach for complete resection of primary gastrointestinal tumors with multiple bilateral liver metastases. J Am Coll Surg 2003 ; 197 : 164-70.
  21. Melendez J, Arslan V, Fisher M et al. Perioperative outcome of major liver resections under low central venous pressure anesthesia : blood loss, blood transfusion, and the risk of postoperative renal dysfunction. J Am Coll Surg 1998 ; 187 : 620-5.
  22. Belghiti J, Noun R, Malafosse R et al. Continuous versus intermittent portal triad clamping for liver resection : A controlled study. Ann Surg 1999 ; 229 : 369-75.
  23. Abdalla E, Noun R, Belghiti J. Hepatic vascular occlusion : which technique ? Surg Clin N Am 2004 ; 84 : 563-85.
  24. Torzilli G, Makuuchi M, Midorikawa Y et al. Liver resection without total vascular exclusion : hazardous or beneficial ? Ann Surg 2001 ; 223 : 167-75.
  25. Yamashita Y, Hamatsu T, Rikimaru T et al. Bile leakage after hepatic resection. Ann Surg 2001 ; 233 : 45-50.
  26. Suc B, Panis Y, Belghiti J, Fekete F. Natural history of hepatectomy. Br J Surg 1992 ; 79 : 39-42.

## استئصال كبدي : تحسن النتائج في مركز العناية الثلاثية في لبنان

**موجز:** الموضوع – دراسة المجموعة حالياً لاستئصالات كبدية يوضح نقصاً في الوفيات والمرضى خلال السنوات العشر الأخيرة. يذكر اصحاب المقالة التقنية الجراحية والاهتمام قبل العملية مما ساعد على الاقلال من الوفيات وهلوي والمرضى لهذه المجموعة.

**الطرق** – مئة استئصال كبدي تحققت تباعاً من ١٩٩٧ الى ٢٠٠٥، درست تهم ملفاً وجمعت المعلومات استرجاعياً.

**النتائج** – كانت الاستطبابات لاورام خبيثة في ٧٣٪. تحقق استئصال كبدي هام في ٥٢٪ من الحالات وتم ذلك دون استعمال ملقط ايقاف الدم في ٤٢٪ من الحالات و٥٧٪ من المرضى لم ينقل اليهم الدم. كانت الوفيات ١٪ ولم تتم الوفاة خلال العملية. وكانت نسبة الاختلاطات ٢٨٪ وسببها الاستئصال الواسع. مدة الاستشفاء الوسطى كانت ١٢ يوماً.

**الخلاصة** – تظهر هذه المجموعة اتصال التقييم ما قبل الجراحة وتوحيد نمط التقنية الجراحية واستعمال التقنية المناسبة لمقط ايقاف الدم والمراقبة الهامة بعد العملية، كل ذلك ادى الى وفاة ١٪ من مجموعتنا التي تم فيها ٥٠٪ استئصال واسع.