

## MISE AU POINT / IN-DEPTH REVIEW RECTOCELE REPAIR • REVIEW AND UPDATE

<http://www.lebanesemedicaljournal.org/articles/59-2/review2.pdf>

Charlotte NGÔ, Richard VILLET, Delphine SALET-LIZÉE, Pierre GADONNEIX\*

Ngô C, Villet R, Salet-Lizée D, Gadonneix P. Rectocele repair: Review and update. J Med Liban 2011 ; 59 (2) : 100-104.

**ABSTRACT: Traiter une rectocèle revient à traiter la paroi postérieure du vagin. Celle-ci comprend trois niveaux : un niveau supérieur (1) correspondant au cul-de-sac vaginal postérieur, un niveau moyen (2) où rectum et vagin sont en contact direct, un niveau inférieur (3) en avant du corps fibreux du périnée. Le traitement tient compte de ou des niveaux atteints. Il peut être fait par voie abdominale, par laparotomie ou par laparoscopie, par voie vaginale et par voie endo-anale. La voie vaginale permet de traiter les trois niveaux alors que la voie abdominale ne permet pas le traitement du niveau 3. La voie endo-anale ne traite que le niveau 2. L'analyse des résultats des différents traitements chirurgicaux est difficile car les niveaux atteints sont mal précisés, des gestes complémentaires souvent effectués dans le même temps opératoire, et le résultat anatomique peut être différent du résultat fonctionnel. Il ressort toutefois que la voie abdominale avec prothèse et promontofixation donne de meilleurs résultats que la voie vaginale et que la cure par voie endo-anale est responsable de plus de récurrences.**

### INTRODUCTION

The term rectocele describes a hernia of the rectal wall – most often anterior – causing an unrolling of the posterior vaginal wall and posterior colpocele. Rectoceles can be associated with elytrocele, with or without bowel or sigmoid loops, and are often associated with other pelvic floor disorders.

Assessment and management of pelvic organ prolapse is practitioner-dependent and the term “rectocele,” in practice, can in fact define different entities without any concordance between anatomical findings and symptoms. Therefore, numerous procedures of rectocele repair have been described, but prospective trials are rare, heavily biased, and difficult to organize. Moreover, analysis of the efficacy of surgical treatments cannot be limited to anatomical outcomes but must also consider functional

outcomes, particularly sexual and defecatory functions, in which both the posterior vaginal wall and anterior rectal wall are concerned.

In this review, we describe anatomy and clinical presentation of rectoceles and review the different methods of surgical treatment. In regard to our personal experience, we propose certain therapeutic indications to correct anatomical and functional defects.

### ANATOMY AND CLINICAL PRESENTATION

Rectoceles have been traditionally classified depending on the anatomical characteristics of the levator ani muscles. However, this description rests solely theoretical because, in practice, the aspect of the levator ani muscles are extremely variable and can be distended, like after an episiotomy, or collapsed, like in descending perineum [1]. Thus the grade of the rectocele is difficult to assess when using the line of levator ani muscles as diagnostic criteria.

In 1987, it was proposed to divide the posterior vaginal wall into three levels [2]. This clinical description was later confirmed by the anatomical studies of DeLancey [3].

**LEVEL 1:** The cranial part of the vagina, suspended by the uterosacral and posterior part of the cardinal ligaments, with the pouch of Douglas, between the anterior rectal wall and posterior vaginal wall.

**LEVEL 2:** The rectum and vagina are in close contact, separated by the rectovaginal fascia, which includes the muscularis layer of the rectum and vaginal stroma, attached laterally to the levator ani arcus tendineus. This part is the longest.

**LEVEL 3:** The rectum and vagina are separated by the perineal body. Level 2 and 3 supports are continuous with one another. Fasciae of the puborectalis muscle are attached to the perineal body. At this level, the ano-rectal angle depends on the strength of the puborectalis levator ani muscles.

According to this anatomical classification, different kind of rectoceles can be observed, depending on the level impaired and the extent of the rectovaginal fascia damages.

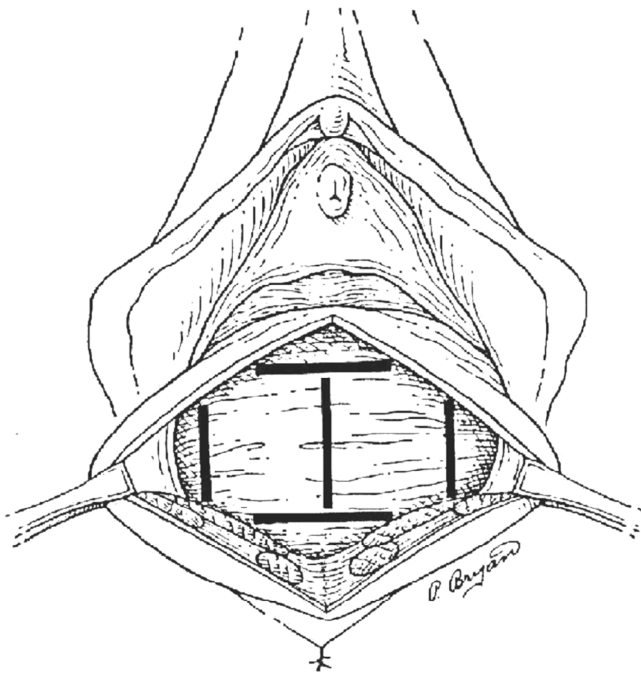
*Proximal rectoceles* (level 1) derive from damage to the uterosacral and cardinal ligaments. The impairment of the level 1 consists in a poorly symptomatic hysteroptosis. In this case, surgeons doing a hysterectomy to rectify anterior and medium prolapses should take into account uterosacral and cardinal ligament damage to avoid a posterior recurrence of the prolapses.

*Middle rectoceles* (level 2) are a herniation through the rectovaginal fascia, linked to a damage of the rectovaginal

\*From the Department of Gynecological and Visceral Surgery, Diaconesses Croix Saint Simon Hospital Center, Paris.

Correspondence: Pr Richard Villet. Service de chirurgie viscérale et gynécologique. Groupe hospitalier Diaconesses Croix Saint Simon. 18 rue du Sergent Bauchat. 75012 Paris. France.  
e-mail: [rvillet@hopital-dcss.org](mailto:rvillet@hopital-dcss.org)

Tel. : +33 1 44 74 10 42 Fax : +33 1 44 74 10 68



**FIGURE 1.** The different locations of rectovaginal fascia damages according to Richardson [4].

connective-tissue and a decreased thickness of the muscularis layer of the anterior rectal wall (Figure 1 describes the different locations of rectovaginal fascia damages according to Richardson [4]).

This hernia can cause feces sequestrum with polyschezia. The mechanism of dyschezia is poorly understood. In our experience, some patients can have a voluminous level 2 rectocele without dyschezia. Dyschezia appears when the feces sequestrum is associated to an obstruction, by paradoxical contraction of levator ani muscles or by intra-anal intussusception before rectal emptying. Those bowel emptying difficulties must be explored by a defecography.

*Distal rectoceles* (level 3) result from a destruction of the perineal body, most often a sequela of episiotomy, with a lateral defect of the puborectalis muscle. In that case, there is a diastasis of the levator ani muscles and an enlarged vulval gap which cause sexual dysfunction, without any bowel dysfunction.

#### DIFFERENT PROCEDURES OF RECTOCELE REPAIR AND THEIR OUTCOMES

There are very few accurate studies comparing different surgical techniques of rectocele repair. Comparison is made difficult by the variability of other pelvic floor disorders often associated with rectoceles in need of specific treatment. Moreover, the rectocele classification that we described is poorly used. Maher et al. published a review of surgical management of pelvic organ prolapse, including posterior vaginal wall prolapse [5], to compare the different procedures.

#### Abdominal sacral colpexy

This approach, by laparotomy [6] or laparoscopy [7-8], can treat only level 1 and level 2 rectoceles. It consists in replacing the vaginal wall with a synthetic mesh. The sigmoid colon is retracted laterally to the left pelvic sidewall, as the peritoneum of the right paracolic gutter is incised from the sacral promontory to the cul-de-sac. The anterior longitudinal sacral ligament is then dissected and two permanent sutures are placed. The part of the procedure treating rectocele consists in a wide dissection of the recto-vaginal fascia down to the perineal body and laterally to the levator ani muscles. A synthetic mesh, attached on the posterior vaginal wall and on the levator ani muscles, is fastened to sacral sutures. The peritoneum is re-approximated over the mesh, avoiding a douglassesctomy.

In their review, Maher et al. conclude that abdominal sacral colpexy is associated with a lower rate of recurrent vault prolapse and dyspareunia than the vaginal sacrospinous ligament fixation, in level 1 rectocele treatment [9-10]. This abdominal approach has a longer operating time, longer convalescence and increased cost but it allows the treatment of other associated pelvic floor disorders.

#### Transanal surgery

This approach can treat only level 2 rectoceles. Anal dilatation is needed, followed by a mucous flap and a rectovaginal fascia repair with a plica of the rectal muscularis layer [11]. This procedure is indicated for moderate level 2 rectoceles associated with rectal prolapse. In case of true intra-anal rectal intussusception, a circular resection of the mucosa and rectal muscularis layer is needed. This can be performed with an automatic stapler (Stapled Trans Anal Rectal Resection STARR) [12].

#### Transvaginal repair

This approach allows the treatment of all three levels.

Treatment of level 1 includes a culdoplasty if necessary and aims to restore a fixed point to the vaginal vault. This can be achieved by suturing uterosacral ligaments together and attach them to the vaginal vault. If uterosacral ligaments are damaged, the vaginal vault can be fixed to the sacrospinous ligament, with a stitch positioned under visual control, or via a sling through the iliococcygeous muscles as described by Von Theobald et al. [13] or, better, through the sacrospinous ligament.

Treatment of level 2 rectoceles consists of plicating the rectovaginal muscularis layer across the midline, using interrupted mattress permanent stitches [14]. This technique shows a cure rate of 80% to 100%, better than site-specific repair with permanent sutures [15]. Abramov et al. reported a failure rate of 32% for site-specific repair as compared to only 13% for the plica of prerectal fascia ( $p = 0.015$ ) [15]. Nieminen et al. showed that this procedure of vaginal repair has better anatomical and functional outcomes than transanal repair [16]. In this study, 29% of patients undergoing vaginal surgery had postoperative dyschezia, as compared to 41% of patients treated with

transanal repair. Recurrence of prolapse occurred in 5% of patients after vaginal surgery compared to 14.5% of patients after transanal surgery. Performing postoperative defecography, Nieminen et al. found a remnant rectocele of 2.73 mm after vaginal surgery and 4.13 mm after transanal repair [16]. Vaginal procedure showed also a lower rate of postoperative enterocele than the transanal method but had more blood losses and more intense immediate postoperative pain. There were no difference between the two groups concerning dyspareunia and anal continence but the anal dilatation that is needed for the transanal repair has been reported to damage the anal sphincter and could compromise anorectal function [17].

Treatment of level 3 includes a perineal repair with distal myorrhaphy of the levator ani muscles. The levator ani myorrhaphy described by Francis and Jeffcoate [18] cannot treat level 1 and level 2 rectoceles but can cause dyspareunia in 30% if performed for this purpose [19-20]. Therefore, this technique should not be used to treat level 1 and level 2 rectoceles. Indeed, levator ani myorrhaphy neither prevent nor correct rectovaginal fascia defects. Jouravleff et al. showed in 1980, in 17 patients with major rectoceles, that eight of them had a previous levator ani myorrhaphy [21]. In 1997, we showed, in a population of 104 patients undergoing abdominal sacral colpopexy with retropubic colpopexy, that 36 patients had a previous levator ani myorrhaphy for enlarged vulva gap [22]. Among those 36 patients, 19 had no preoperative rectocele and 17 had preoperative rectocele. In those two groups, 6 patients and 5 patients, respectively, presented a rectocele within five years after abdominal sacral colpopexy. Those data are summarized in table I.

However, the efficiency of treatment of posterior vaginal wall prolapse with synthetic mesh is not proven. Synthetic mesh could be used for treatment of rectoceles of the three levels.

Level 1 suspension can be treated with the Posterior Intravaginal Sling Plasty (PIVS) technique, using a polypropylene multifilament band passed through the sacrospinous ligament via a transgluteal approach [13]. This procedure has the same anatomical outcomes as the vaginal sacrospinous colpopexy [23].

Treatment of level 2 rectoceles can be achieved by augmentation of the rectovaginal fascia with a mesh, as first

described by Parker and Philipp [24]. The mesh can be placed without any suture but the risk of retraction is high and the area of the mesh can be reduced of 30% from its original size [25]. Therefore, the mesh can be secured superiorly to the vagina and/or to the uterosacral ligaments, and/or to a PIVS if this procedure is associated. Laterally, the mesh is attached to the levator ani fascia and inferiorly to the perineal body. For the same purpose, this inter-rectovaginal mesh can be prolonged with lateral superior arms fixed to the sacrospinous ligaments or passed through them via a transgluteal approach [26]. Synthetic mesh use has to be limited since the risk of complications such as erosion, exposition, pain and dyspareunia, is high and since vaginal surgery without mesh has good outcomes. The use of organic grafts showed a lower rate of complications but a higher rate of failure. Indeed, in a prospective trial, Paraiso et al. showed that the use of porcine grafts decreased the risk of erosion but increased the risk of recurrence compared to vaginal plica [27]. Those results were confirmed by Altmann's study for Pelvicol [28].

#### SURGICAL INDICATIONS

Rectoceles must be treated if symptomatic or to prevent them to become symptomatic if co-morbid with another pelvic floor disorder that is to be treated.

Level 3 rectoceles must be treated if patients complain of sexual dysfunction, and moreover, if levator ani muscles are damaged. The repair of level 3 rectoceles consists of a levator ani myorrhaphy of 1 to 2 cm anteriorly to the anus. The repair of the perineal body can prevent a prolapse of anterior vaginal wall, creating a posterior resistance to abdominal pressure.

Level 2 rectoceles must be treated when severe dyschezia is associated. Prior to surgery, defecography is necessary to allow the diagnosis of intra-anal rectal intussusception. If there is no intussusception and no other pelvic organ prolapse associated, vaginal repair of rectovaginal fascia is the best choice. If needed, suspension of the vaginal vault can be associated with sacrospinous ligament fixation or uterosacral ligaments plasty. If there is an intra-anal rectal intussusception, a transanal resection is indicated (STARR or TRANS-STARR). Evaluation of

**TABLE I**  
RECURRENT POSTERIOR PROLAPSE AFTER MYORRHAPHY\*

	NO PRE-OPERATIVE RECTOCELE n = 61		PRE-OPERATIVE RECTOCELE n = 43		N
	-	+	-	+	
<b>Myorrhaphy</b>	-	+	-	+	
<b>No postoperative rectocele</b>	41	13	24	12	<b>90</b>
<b>Postoperative rectocele</b>	1	6	2	5	<b>14</b>

\*Ref. 22. Villet R, Mandron E, Salet-Lizee D et al. [Surgical treatment of genito-urinary prolapse by abdominal approach with promotofixation and setting of an anterior subvesical prosthesis combined with retropubic colpopexia: anatomical and functional results in 104 patients]. *Chirurgie* 1997 ; 122 : 353-8; discussion 358-9.

this technique is being processed by different studies.

Level 1 rectoceles are always associated with hysteroptosis or ptosis of the vaginal cuff and ptosis of the pouch of Douglas. Their treatment consists in an abdominal sacral colpopexy with an inter-rectovaginal prosthesis, placed as low as needed, depending on the severity of the level 2 rectocele associated.

Often, rectoceles are a consequence of previous surgery with anterior vaginal wall repair and anterior suspension, like sacral colpopexy with vesicovaginal hamac and retropubic colpopexy. The strengthening of one compartment increases the fragility of the others, creating an anteroposterior dysequilibrium, or what we call a "remoulding effect". If anterior and medium compartments are still fixed, those rectoceles can be treated using an abdominal or vaginal approach. The abdominal approach consists in a wide rectovaginal dissection to put a synthetic mesh as low as possible, attached to anterior sacral ligament. For this purpose, the anterior mesh is cut and re-attached after positioning the posterior mesh. This can be done by laparotomy or laparoscopy. The vaginal approach consists in a sagittal colpotomy, dissection of the anterior rectal wall and plica of the prerectal fascia with permanent sutures. The vaginal vault is suspended with sacrospinous ligaments fixation with vaginal flaps.

Finally, if the rectocele is associated with other pelvic organ prolapse, the best procedure is abdominal sacral colpopexy with two prosthesis – prevaginal and retrovaginal. However, vaginal surgery is conceivable to treat the three levels. The therapeutic choice will ultimately depend on patient wishes and the surgeon skills.

#### CONCLUSION

Surgical treatment of rectoceles, as with any pelvic floor disorder, should be indicated depending on functional impacts more than anatomical defects. It should take into account the patient's age, life expectancy, sexual activity and anesthetic restraints. The choice between abdominal or vaginal surgery will depend on symptoms, anatomical defects, patient wishes but also on surgical skill. Pre-operative analysis of both anatomical defects, with the level impaired, and functional complaints, with complementary examination to explore dyschezia, is essential for choosing the best procedure for the best result.

#### ACKNOWLEDGMENTS

The authors are indebted to Dr Andrew Wang for reviewing the manuscript.

#### REFERENCES

1. Villet R, Ayoub N, Salet-Lizee D, Bolner B, Kujas A. [Descending perineum in women]. *Prog Urol* 2005 ; 15 : 265-71.
2. Villet R. Rectoceles and posterior colpoceles : clinical and therapeutic aspects. *Med Chir Dig* 1987 ; 16 : 583-8.
3. DeLancey JO. Structural anatomy of the posterior pelvic compartment as it relates to rectocele. *Am J Obstet Gynecol* 1999 ; 180 : 815-23.
4. Richardson AC. The rectovaginal septum revisited : its relationship to rectocele and its importance in rectocele repair. *Clin Obstet Gynecol* 1993 ; 36 : 976-83.
5. Maher C, Baessler K, Glazener CM, Adams EJ, Hgen S. Surgical management of pelvic organ prolapse in women. *Cochrane Database Syst Rev* 2007 : CD004014.
6. Villet R, Morice P, Bech A, Salet-Lizee D, Zafirapulo M. [Abdominal approach of rectocele and colpocele]. *Ann Chir* 1993 ; 47 : 626-30.
7. Gadonneix P, Ercoli A, Scambia G, Villet R. The use of laparoscopic sacrocolpopexy in the management of pelvic organ prolapse. *Curr Opin Obstet Gynecol* 2005 ; 17 : 376-80.
8. Paraiso MF, Walters MD, Rackley RR, Melek S, Hugney C. Laparoscopic and abdominal sacral colpopexies : a comparative cohort study. *Am J Obstet Gynecol* 2005 ; 192 : 1752-8.
9. Benson JT, Lucente V, McClellan E. Vaginal versus abdominal reconstructive surgery for the treatment of pelvic support defects : a prospective randomized study with long-term outcome evaluation. *Am J Obstet Gynecol* 1996 ; 175 : 1418-21 ; discussion 1421-2.
10. Maher CF, Qatawneh AM, Dwyer PL et al. Abdominal sacral colpopexy or vaginal sacrospinous colpopexy for vaginal vault prolapse : a prospective randomized study. *Am J Obstet Gynecol* 2004 ; 190 : 20-6.
11. Sullivan ES, Leaverton GH, Hardwick CE. Transrectal perineal repair : an adjunct to improved function after anorectal surgery. *Dis Colon Rectum* 1968 ; 11 : 106-14.
12. Altomare DF, Rinaldi M, Veglia A et al. Combined perineal and endorectal repair of rectocele by circular stapler : a novel surgical technique. *Dis Colon Rectum* 2002 ; 45 : 1549-52.
13. Von Theobald P, Labbe E. [Posterior IVS : feasibility and preliminary results in a continuous series of 108 cases]. *Gynecol Obstet Fertil* 2007 ; 35 : 968-74.
14. Lehur PA, Kahn X, Hamy A. [Surgical treatment of anterior rectoceles in women. The perineal-vaginal approach]. *Ann Chir* 2000 ; 125 : 782-6.
15. Abramov Y, Gandhi S, Golberg RP et al. Site-specific rectocele repair compared with standard posterior colporrhaphy. *Obstet Gynecol* 2005 ; 105 : 314-18.
16. Nieminen K, Hiltunen KM, Laitinen J, Oksala J, Heinonen PK. Transanal or vaginal approach to rectocele repair : a prospective, randomized pilot study. *Dis Colon Rectum* 2004 ; 47 : 1636-42.
17. Roman H, Michot F. Long-term outcomes of transanal rectocele repair. *Dis Colon Rectum* 2005 ; 48 : 510-17.
18. Francis WJ, Jeffcoate TN. Dyspareunia following vaginal operations. *J Obstet Gynaecol Br Commonw* 1961 ; 68 : 1-10.
19. Kahn MA, Stanton SL. Posterior colporrhaphy: its effects on bowel and sexual function. *Br J Obstet Gynaecol* 1997 ; 104 : 82-6.
20. Mellgren A, Anzen B, Nilsson BY et al. Results of rectocele repair. A prospective study. *Dis Colon Rectum* 1995 ; 38 : 7-13.
21. Jouravleff M. Problèmes thérapeutiques des rectocèles à la lumière des résultats des rectopexies. *Entretiens de Bichat, Paris*, 1980 : 121-5.
22. Villet R, Mandron E, Salet-Lizee D et al. [Surgical treat-

- ment of genito-urinary prolapse by abdominal approach with promotofixation and setting of an anterior sub-vesical prosthesis combined with retropubic colpopexia : anatomical and functional results in 104 patients]. *Chirurgie* 1997 ; 122 : 353-8 ; discussion 358-9.
23. Meschia M, Pifarotti P, Spennacchio M et al. A randomized comparison of tension-free vaginal tape and endopelvic fascia plication in women with genital prolapse and occult stress urinary incontinence. *Am J Obstet Gynecol* 2004 ; 190 : 609-13.
  24. Parker MC, Phillips RK. Repair of rectocele using Marlex mesh. *Ann R Coll Surg Engl* 1993 ; 75 : 193-4.
  25. Debodinance P, Berrocal J, Clave H et al. [Changing attitudes on the surgical treatment of urogenital prolapse : birth of the tension-free vaginal mesh]. *J Gynecol Obstet Biol Reprod (Paris)* 2004 ; 33 : 577-88.
  26. Fatton B, Amblard J, Debodinance P, Cosson M, Jacquelin B. Transvaginal repair of genital prolapse : preliminary results of a new tension-free vaginal mesh (Prolift technique) – a case series multicentric study. *Int Urogynecol J Pelvic Floor Dysfunct* 2007 ; 18 : 743-52.
  27. Paraiso MF, Barber MD, Muir TW, Walters MD. Rectocele repair : a randomized trial of three surgical techniques including graft augmentation. *Am J Obstet Gynecol* 2006 ; 195 : 1762-71.
  28. Altman D, Zetterstrom J, Mellgren A et al. A three-year prospective assessment of rectocele repair using porcine xenograft. *Obstet Gynecol* 2006 ; 107 : 59-65.