

CAS CLINIQUE / CASE REPORT

ACUTE PANCREATITIS COMPLICATING SEVERE PREECLAMPSIA

A Case Report

<http://www.lebanesemedicaljournal.org/articles/68-3/case2.pdf>

Hisham ZA'AROUR^{1,2}, Saadieh AL-SHEIKH², Loubna SINNO³, Jihad AL-HASSAN², Mohamad K. RAMADAN^{1,4,5*}

Za'arour H, Al-Sheikh S, Sinno L, Al-Hassan J, Ramadan M.K. Acute pancreatitis complicating severe preeclampsia. A case report. *J Med Liban* 2020; 68 (3): 160-163.

Za'arour H, Al-Sheikh S, Sinno L, Al-Hassan J, Ramadan M.K. Un cas de pancréatite aiguë compliquant une prééclampsie sévère. *J Med Liban* 2020; 68 (3): 160-163.

ABSTRACT • Acute pancreatitis outside or during pregnancy is an unusual condition commonly triggered by biliary disease, with other less frequent causes being viral, alcoholism and hypertriglyceridemia. In extremely rare instances, it has been reported to be associated with severe preeclampsia. The mechanism, here, is believed to be part of a widespread endothelial damage responsible for the appearance of preeclampsia itself. Hereby, we report a case of postpartum transient acute pancreatitis in a patient with severe preeclampsia. The peculiar appearance of excruciating epigastric pain radiating to the back on first post-operative day prompted a complete work-up which disclosed leukocytosis, elevated amylase and lipase, whereas ultrasonography of the liver and biliary system together with CT scan done few days later were completely normal. Though the course of this particular case was benign, with rapid spontaneous improvement following supportive therapy, yet, this condition could have led to the severe necrotizing form associated with detrimental maternal and neonatal outcomes if not recognized early and managed properly. Acute pancreatitis should be part of the differential diagnosis of epigastric pain among peripartum women especially those with severe preeclampsia.

Keywords: acute epigastric pain; acute pancreatitis; postpartum period; preeclampsia

RÉSUMÉ • La pancréatite aiguë, durant ou hors grossesse, est une condition rare souvent déclenchée par une pathologie biliaire, et d'autres causes moins fréquentes: l'infection virale, l'alcoolisme ou l'hyperlipidémie. Dans des cas extrêmement rares, l'association avec la prééclampsie est décrite dans la littérature. Nous rapportons ici un cas de pancréatite aiguë transitoire en post-partum chez une patiente atteinte de prééclampsie sévère. L'apparition de douleur intense au niveau épigastrique et de l'hypochondre droit irradiant au dos le premier jour postopératoire, a incité à faire un bilan complet qui a révélé une leucocytose, une élévation de l'amylase et de la lipase, mais une échographie normale du foie, avec tomodensitométrie normale quelques jours plus tard. Malgré un parcours médical avec une amélioration spontanée rapide suite à un traitement de soutien, cette condition peut potentiellement conduire à la forme nécrosante grave avec des résultats maternels et néonataux préjudiciables, si non reconnus dès le début et bien gérés. Chez toute femme avec douleurs épigastriques périnatales, spécialement celles accompagnées d'une prééclampsie sévère, le diagnostic différentiel devra inclure la pancréatite aiguë.

Mots-clés: douleur épigastrique aiguë; pancréatite aiguë; post-partum; prééclampsie

INTRODUCTION

Acute pancreatitis (AP) is an infrequent encounter during pregnancy. The clinical course can range from transitory mild pancreatic inflammation to a life-threatening necrotizing pancreatitis. As in general population, biliary disease with gallstones is the main etiology for pancreatitis during pregnancy. [1] An extremely rare association of AP with preeclampsia/HELLP syndrome has been previously reported. [2,3] Preeclampsia is a multisystem disorder of pregnancy that is believed to be the result of widespread endothelial dysfunction affecting the microvasculature of multiple organs that can afflict the pancreas as well. [3,4] Another plausible cause for pancreatitis among patients with severe

preeclampsia might be attributable to loop diuretics commonly used in the management of oliguria. [5]

Hereby, we present a case of severe preeclampsia complicated by hepatic and renal injuries and found to develop new-onset epigastric pain on first postpartum day together with laboratory evidence of pancreatitis. We also present a synopsis of the work-up required in the management of AP in pregnancy.

CASE DESCRIPTION

A 39-year-old G1P0 healthy woman, with smooth prenatal course was admitted to our maternity unit with labor pain at 38 weeks' gestation. Upon admission, the blood pressure

¹Department of Obstetrics and Gynecology, Faculty of Medicine and Public Health, Lebanese University, Beirut, Lebanon.

²Department of Obstetrics and Gynecology, Zahraa' Hospital, Beirut.

³Research-Unit Coordinator, Makassed General Hospital, Beirut.

⁴Departments of Obstetrics and Gynecology, Makassed General Hospital. Beirut.

⁵Department of Obstetrics and Gynecology, Rafic Hariri University Hospital. Beirut.

*Corresponding author: *Mohamad K. Ramadan, MBBCH-FACS*

e-mail: mkr538@gmail.com

(BP) was 130/90 mmHg, pulse 114 BPM. She was prepared for caesarian delivery due to transverse fetal lie. Her laboratory tests were as follows: hemoglobin 15.1 g/dl; platelets count 227 x10⁹/L; WBCs 13,600 with normal PT and PTT results. Under general anesthesia, a healthy female newborn was delivered with good Apgar score.

Operative course was without incidents but a sudden BP reading of 200/100 mmHg in the immediate postpartum period was recorded. This was treated with IV Labetalol in the recovery room. Magnesium sulfate 6g IV loading dose was initiated followed by 2g/h maintenance for eclampsia prophylaxis. Her preeclampsia profile was as follows: uric acid 9.8 mg/dl; creatinine 1.19 mg/dl; SGOT 195 U/L; SGPT 289 U/L; LDH 292 U/L. Urine analysis was negative for protein. Overnight BP was controlled with normal deep tendon reflexes, generalized pitting edema and good urine output.

The following morning her laboratory tests revealed a sudden elevation of WBCs count to 45,000, Hb of 13.1 g/dl and a normal platelets count. Repeat WBCs count confirmed the previous value. This leukocytosis was alarming and the primary source was not determined while the patient was still afebrile and asymptomatic. Liver function tests (LFTs) slightly dropped to 177 U/L for SGOT and 197 U/L for SGPT, uric acid 9.4 mg/dl. Electrolytes showed high anion gap with metabolic acidosis. Creatinine became 1.39 mg/dl.

Repeat laboratory values 6 hours later showed Hb of 12.8 mg/dl, platelets of 221 x 10⁹/dl and WBCs of 50,000. At this time, the patient started complaining of acute new-onset epigastric pain radiating to the back (not related to the cesarean wound) with headache and blurred vision. Upon physical exam, the abdomen was soft with epigastric tenderness and hypoactive bowel.

Abdominal ultrasound did not show any gall stones or sign of cholecystitis or liver abnormalities except for mild ascites that was explained by third-spacing induced by preeclampsia. Laboratory tests showed highly elevated lipase 2069 U/L and amylase 754 U/L pointing to the existence of AP. Additional laboratory tests showed: SGOT 69 U/L; SGPT 115 U/L; LDH 246 U/L; random glucose level 105 mg/dl; calcium level 7.8 corrected to albumin; creatinine 1.32 mg/dl; uric acid 9.0 mg/dl and normal PT-PTT. Direct bilirubin was 0.2 mg/dl and 0.41 for total.

The clinical status of the patient, however, was reassuring. Measures were taken to adjust IV hydration and to start bowel rest. BP was maintained at < 140 systolic and at < 90 diastolic. Diuretics were not used. Magnesium level remained within therapeutic levels with good urine output and normal neurologic exam. The patient was kept under intensive monitoring and frequent physical exams. On the second postoperative day, the patient felt better with significant attenuation of her pain and headache. MgSO₄ was discontinued. The patient started ambulation with audible bowel sounds. Laboratory values showed improvement of lipase to 876 U/L and amylase to 595 U/L together with near normalization of LFTs and electrolytes while creatinine became 1.21 mg. WBCs dropped to 20,000.

On day-3 postoperatively, the vital signs continued to be stable with normal BP. Soft diet was initiated and was well tolerated. Additional normalization of laboratory values was observed, where creatinine dropped to 0.71 so a CT scan with IV contrast of abdomen was allowed.

It showed no signs suggestive of associated complications (Figure 1). The patient was discharged home in stable condition, on antihypertensive medications and instructions of BP charting.

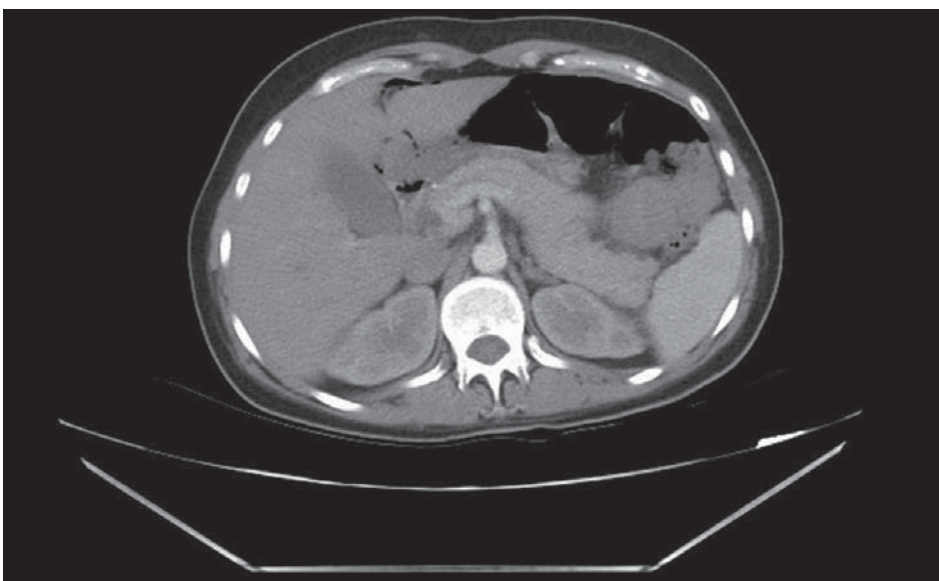


Figure 1
Axial enhanced CT of the abdomen showing normally outlined pancreas (Baltazar stage 0).

At 6-weeks follow-up visit, she was healthy with normal BP and normal lipid profile which affirmed the impression that her acute pancreatitis could have been related to preeclampsia.

DISCUSSION

We report hereby the case of a full-term healthy parturient with postpartum severe preeclampsia who was also found to develop AP one day after delivery. The transient nature with the rapid amelioration of epigastric pain and normalization of pancreatic enzymes that paralleled improvement of preeclampsia, together with the absence of any commonly identifiable cause, compelled us to relate these findings to severe preeclampsia.

In a series collected at one center over ten years, the incidence of AP among pregnant woman was 1/3333, with 70% attributed to biliary pathology and 97% of which occurred in the antepartum period, and interestingly, none was associated with preeclampsia. [6] The exact incidence of AP in association with severe preeclampsia/HELLP syndrome is not clear, but it seems to be exceedingly rare. A study by Sang *et al.* in 2017 reported that AP complicated 1.2% of cases with severe preeclampsia among their Chinese population. [2] A literature review by Hojo *et al.* in 2007 identified only 15 cases and added one at their hospital. They could find no identifiable cause and again the course was benign with rapid resolution without complications, similar to our case. [3] Conversely, others reported cases of AP concurrent with severe preeclampsia/HELLP syndrome but with catastrophic fulminant pancreatic necrosis or multi-organ failure [3,7], or even mortality in spite of multidisciplinary intensive management. [8,9] The mechanism of this association has not been well elucidated, though it is believed to be part of a widespread endothelial damage responsible for the appearance of preeclampsia itself. [3,4] Unlike cases triggered by biliary disease, most cases associated with preeclampsia occurred either during the third trimester (mean 32 weeks), [2] or directly postpartum. [3] When AP coinciding with preeclampsia/HELLP syndrome infrequently appears antepartum, the recommended management is rapid termination of pregnancy with delivery. [4] Another observation specific to severe preeclampsia is the propensity to develop AP when loop diuretics were used in the setting of management of oliguria. [5]

In general, and similar to AP outside pregnancy, a systematic approach is followed in the diagnosis and management during pregnancy. The diagnosis requires the presence of at least two of the following three criteria: characteristic epigastric pain radiating to the back; elevated serum amylase/lipase > 3 times the normal range;

characteristic findings on CT scan. Usually it is accompanied with fever, nausea/vomiting and epigastric tenderness. There might also be hyperglycemia, hypoalbuminemia, electrolyte and calcium abnormalities. The clinical course might be insidious and mild, or very infrequently, stormy with rapid deterioration and catastrophic maternal and perinatal outcomes. Severity can be assessed with initial APACHE-II score > 8, Hct > 44 or CRP > 150. These markers are surveyed continuously to monitor the course of the condition. Ranson clinical scoring commonly used in general population has not been validated in pregnancy.

The next step is to identify the underlying triggering factor. Ultrasound of gall bladder and biliary tract is the most specific imaging tool in excluding a biliary pathology. CT scan with enhancement is the modality of choice of imaging at all emergency departments for cases presenting with acute abdomen including AP, during and outside pregnancy. Its unequivocal value is in clinically deteriorating cases for detecting related complications that may require surgical intervention, e.g. duodenal pseudocysts, infected peripancreatic abscess and hemorrhagic necrosis. AP can be classified and managed using CT scan staging according to Balthazar severity index. [10] Furthermore, CT scan can be of benefit in the initial diagnosis of ambiguous cases where symptoms are subtle or laboratory tests are borderline; however, it is recommended to be done 48 hours after the appearance of pain as radiologic changes might not be evident yet. [11] Many clinicians preserve this imaging modality for deteriorating or unrelenting cases, hence, the clinical judgment is usually what determines the need for imaging with CT scan or MRI. In mild cases, irrespective of the underlying etiology, medical supportive therapy alone could be sufficient, while surgical intervention is preserved for associated complications.

The preferred supportive therapy usually includes bowel rest, IV hydration, correction of calcium, electrolyte imbalance and pain management. [4] Surgical treatment, especially for underlying biliary pathology, is better postponed till the postpartum period when inflammation subsides, unless the condition does not ameliorate with supportive therapy or recurrence occurs or cholangitis ensues. Here, and during pregnancy, endoscopic intervention together with shielding of the abdomen is the preferred intervention. Diet manipulation, lipid and even serial plasmapheresis can be used in hypertriglyceridemia-induced AP with possible delivery when appropriate. [12] Although our case improved rapidly and the need for CT scan was not necessary, yet, the rarity and uniqueness of the association of severe preeclampsia with AP compelled us to proceed with this imaging modality. CT was done on day three, when cre-

atinine normalized. Findings were consistent with normal pancreas (Baltazar 0) confirming the clinical mildness of the condition in accordance with the clinical and laboratory assessments. (Figure 1)

In summary, this patient with severe preeclampsia developed, 24 hours after cesarean delivery, new-onset severe epigastric pain radiating to the back together with leukocytosis, elevated pancreatic enzymes, all of which were highly suggestive of AP. A negative ultrasound excluded the presence of biliary pathology. Supportive therapy was initiated followed by rapid improvement of the condition. A noteworthy observation was the fast resolution of pancreatitis paralleling the improvement of preeclampsia, possibly by elimination of the vascular insult on the pancreas. A similar case of AP complicating severe preeclampsia was reported by Chan *et al.* in 2018. [13] Their patient also presented with out-of-proportion abdominal pain after caesarean section which prompted investigations that led to the diagnosis of AP.

CONCLUSION

Early identification and appropriate treatment of the specific cause remain the cornerstone of sound management of pancreatitis during and outside pregnancy. The undisputable merit of early diagnosis is to permit the timely initiation of interventions needed in complicated forms of AP. New-onset upper abdominal pain should instigate serious and meticulous work-up to exclude the existence of AP especially among women with severe preeclampsia.

ACKNOWLEDGMENT

We are grateful to the guidance and precious assistance provided by Omar Sheikh-Taha, MD. (Radiology Department, Makassed General Hospital).

CONFLICT OF INTERESTS: None to declare.

PATIENT CONSENT: Obtained.

REFERENCES

1. Jeon SY, Jung E, Seol HJ, Hur YJ. Development of Purtscher-like retinopathy after preeclampsia combined with acute pancreatitis. *Obstet Gynecol Sci* 2013; 56: 261-4.
2. Sang C, Wang S, Zhang Z, Lu J. Characteristics and outcome of severe preeclampsia/eclampsia concurrent with or complicated by acute pancreatitis: a report of five cases and literature review. *J Matern Fetal Neonatal Med* 2017; 18: 1-8.
3. Hojo S, Tsukimori K, Hanaoka M et al. Acute pancreatitis and cholecystitis associated with postpartum HELLP syndrome: a case and review. *Hypertens Pregnancy* 2007; 26: 23-29.
4. Barton JR, Sibai BM. Gastrointestinal complications of pre-eclampsia. *Semin Perinatol* 2009; 33: 179-188.
5. Marcovici I, Marzano D. Pregnancy-induced hypertension complicated by postpartum renal failure and pancreatitis: a case report. *Am J Perinatol* 2002; 19: 177-180.
6. Ramin KD, Ramin SM, Richey SD, Cunningham FG. Acute pancreatitis in pregnancy. *Am J Obstet Gynecol* 1995; 173: 187-191.
7. English N, Rao J. Acute fatty liver of pregnancy with hypoglycaemia, diabetes insipidus and pancreatitis, preceded by intrahepatic cholestasis of pregnancy. *BMJ Case Reports* 2015; 2015.
8. Swank M, Nageotte M, Hatfield T. Necrotizing pancreatitis associated with severe preeclampsia. *Obstet Gynecol* 2012; 120: 453-455.
9. Gainer S, Arora P, Saha SC, Kaman L. Acute pancreatitis with eclampsia-preeclampsia syndrome and poor maternal outcome: two case reports and review of literature. *Obstet Med* 2015; 8: 146-148.
10. Arvanitakis M, Koustiani G, Gantzarou A et al. Staging of severity and prognosis of acute pancreatitis by computed tomography and magnetic resonance imaging - a comparative study. *Dig Liver Dis* 2007; 39: 473-482.
11. Ducarme G, Maire F, Chatel P, Luton D, Hammel P. Acute pancreatitis during pregnancy: a review. *J Perinatol* 2014; 34: 87-94.
12. Tsuang W, Navaneethan U, Ruiz L, Palascak JB, Gelrud A. Hypertriglyceridemic pancreatitis: presentation and management. *Am J Gastroenterol* 2009; 104: 984-991.
13. Chan C, Mukerji M. Non-gallstone acute pancreatitis and pre-eclampsia: A case report. *Case Rep Women Health* 2018; 19: e00063.