

CAS CLINIQUE / CASE REPORT

ENDOTRACHEAL HAMARTOCHONDROMA

A Case Report

<http://www.lebanesemedicaljournal.org/articles/68-3/case3.pdf>

Ali AKIL^{1*}, Stefan FISCHER¹

Akil A, Fischer S. Endotracheal hamartochondroma : A case report. J Med Liban 2020; 68 (3) : 164-165.

ABSTRACT • Benign tracheal tumors are rare with few singular cases described. Endotracheal hamartochondroma represents one of those benign tracheal tumors. We report here the case of 75-year-old female with a symptomatic endotracheal hamartochondroma originating 0.5 cm above the carina and occluding the right main bronchus. This benign tumor was resected successfully and the patient was discharged after 7 days from the hospital. Despite sporadic reports in the literature, hamartochondroma of the trachea still remain extremely rare and the diagnosis is always made by coincidence. The only leading symptom of such tumor is dyspnea. Otherwise, they remain undiagnosed.

Keywords : hamartochondroma; trachea; thoracotomy

INTRODUCTION

Benign endobronchial tumors are rare entities [1]. The term hamartochondroma or chondroma of the lung was initially introduced in 1934 to define benign tumors located predominantly in the lung and made of fat and cartilage [2]. Furthermore, several studies enrolling patients with endobronchial hamartomas showed that those benign findings have a low frequency of occurrence and are mostly incidental findings [3-5]. In contrast, only singular cases of benign tracheal tumors were reported previously [6-7]. Few data about their histological origin and about their treatment are collected.

Here, we present a rare case of a patient with a symptomatic endotracheal hamartochondroma located above the carina.

CASE DESCRIPTION

We report the case of a 75-year-old female with a symptomatic endotracheal hamartochondroma located in the trachea, 0,5 cm above the carina. The patient was admitted to our department with a 2-month history of progressive dyspnea and stridor. In her past medical history, idiopathic unilateral left-sided diaphragm paralysis was diagnosed. When admitted to our hospital, the chest X-

Akil A, Fischer S. Étude d'un cas d'hamartochondrome endotrachéal : J Med Liban 2020; 68 (3) : 164-165.

RÉSUMÉ • Les tumeurs bénignes de la trachée sont rares avec quelques cas décrits. Les hamartochondromes endotrachéaux en font partie. Nous rapportons ici le cas d'une femme de 75 ans présentant un hamartochondrome endotrachéal symptomatique à 0,5 cm au-dessus de la carène obstruant la bronche principale droite. Cette tumeur bénigne a été résectionnée avec succès et la patiente a été libérée après 7 jours d'hospitalisation. Malgré des rapports sporadiques dans la littérature, les hamartochondromes de la trachée restent encore extrêmement rares et le diagnostic est toujours fait par hasard. Le seul symptôme principal d'une telle tumeur est la dyspnée. Sinon, ils restent non diagnostiqués.

Mots-clés : hamartochondrome; trachée; thoracotomie

ray showed a right side elevated hemidiaphragm and right basal subsegmental atelectasis. Unexpectedly, the computed tomography (CT) scan of the chest and neck revealed a rounded circumscribed endotracheal tumor originating 0.5 cm above the carina and approaching the right main bronchus with observable chondral calcification in the left and right main stem bronchus (Figure 1).

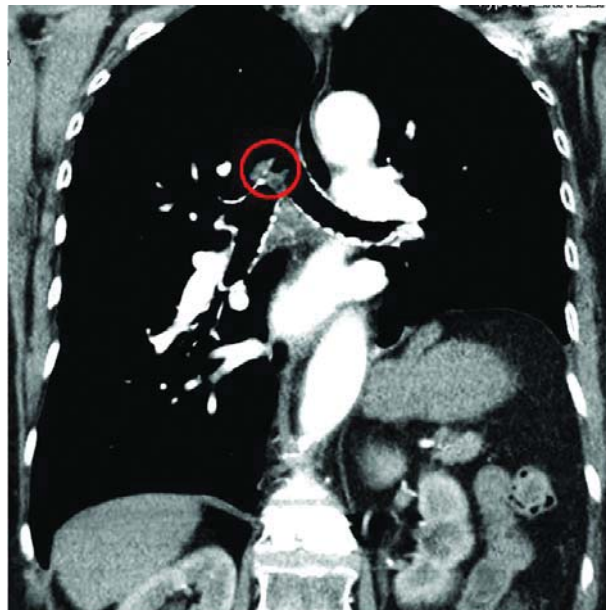


Figure 1. Chest-CT
Centrally located hamartochondroma with chondral calcification of the cartilaginal rings

¹Department of Thoracic Surgery & Lung Support, Ibbenbueren General Hospital, Ibbenbueren, Germany.

*Corresponding author: *Ali Akil, MD.*
e-mail: dr.ali.akil.11@gmail.com

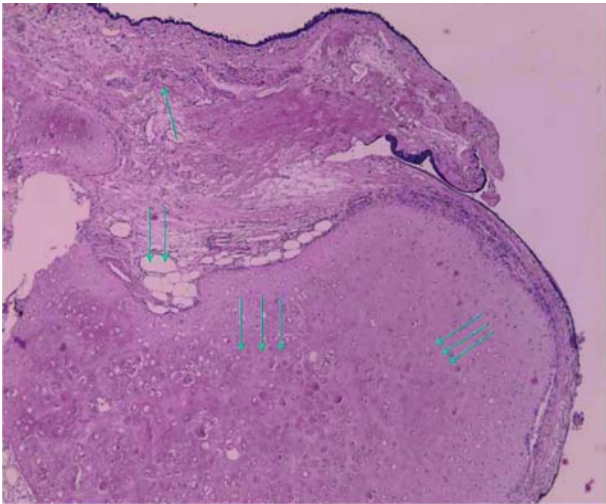

Figure 2. Histopathology

Histological section shows the typical respiratory epithelium (→), hyaline cartilage cell structures (⇔) and giant adipocytes (⇓), revealing the microscopic features of a hamartochondroma.

Speckled or popcorn type calcifications could be seen in the left and right main bronchus. Flexible bronchoscopy revealed a tumor mass with a wide base involving the right posterolateral side of the carina and reaching the right main bronchus. Due to the tumor size and total right main bronchus occlusion during inspiration, surgical resection was considered.

A right-sided lateral thoracotomy was performed. The lower end of the trachea including the right posterolateral side of the bifurcation and one centimeter of the proximal right main bronchus were resected. Subsequently, anastomosis between the right main bronchus and the trachea was achieved by non-interrupted sutures.

Histopathological investigation revealed a benign hamartochondroma (Figure 2). The postoperative course was uneventful. The patient was discharged on POD 7.

DISCUSSION

Hamartochondroma represents one of the most common benign tumors of the lung [1]. They usually arise intraparenchymally (90%) and the remaining part endobronchially or endotracheally (10%). In general, they reveal a very low risk of malignancy and a low rate of recurrence. Usually, most hamartochondromas of the lung are often found incidentally and rarely symptomatic [8]. It has been reported in many clinical cases that patients with lung hamartomas and endobronchial hamartochondromas mostly do not show any symptoms at the time of diagnosis. Furthermore, they are mostly an incidental

radiographic finding [2-4]. In contrast, endobronchial or endotracheal hamartochondromas can cause obstruction of the respiratory tract with dyspnea and less often hemoptysis, which are mostly the leading symptoms for diagnosis. In such cases, surgical resection is the mainstay approach. Alternatively, when possible, endobronchial hamartomas can be resected via rigid bronchoscopy or electrocautery and argon plasma ablation via fiberoptic bronchoscopy [9-10].

The herein case depicts a patient who suffered from progressive dyspnea due to a tracheal hamartochondroma. The diagnosis was made by coincidence. The CT-image showed an unusual chondral calcification of nearly all tracheal and large bronchial cartilaginal rings beside the centrally located mass. Histopathological findings revealed the microscopic features of a hamartochondroma. This benign tumor was resected successfully and the patient was discharged from the hospital after seven days.

Despite sporadic reports in the literature, hamartochondroma still remains extremely rare and the diagnosis is almost associated with the beginning of the symptoms. The only leading symptom of such tumor is dyspnea. Otherwise, they remain undiagnosed.

REFERENCES

- McDonald JR, Harrington SW, Clagett OT. Hamartoma (often called chondroma) of the lung. *J Thorac Surg* 1945; 14: 128-43.
- Goldsworthy NE. Chondroma of lung (hamartoma chondromatosum pulmonis), with report of case. *J Pathol Bacteriol* 1934; 39: 291-8.
- Gjevre JA, Myers JL, Prakash UB. Pulmonary hamartomas. *Mayo Clin Proc* 1996; 71: 14-20.
- Van den Bosch JM, Wagenaar SS, Corrin B et al. Mesenchymoma of the lung (so called hamartoma): a review of 154 parenchymal and endobronchial cases. *Thorax* 1987; 42: 790-3.
- Sibala JL. Endobronchial hamartomas. *Chest* 1972; 62: 631-4.
- Iusco D, Bobbio A, Donadei E, Carbognani P. Hamartochondroma arising from a tracheal bronchus. *Chir Ital* 2007; 59 (2): 253-5.
- Cetinkaya E, Gunluoglu G, Eyhan S et al. A hamartoma located in the trachea. *Annals of Thoracic and Cardiovascular Surgery* 2011; 17 (5): 504-6.
- Bail DH, Hammer SP, editors. *Pulmonary Pathology*; 2nd edition, New York: Springer Verlag, 1995: 1368-74.
- Ortiz-Saracho J, Picher J, Garcia-Rull S, Reboiras SD, Perez I. Endobronchial hamartoma resected by rigid bronchoscope. *Eur J Cardiothorac Surg* 1993; 7: 445-6.
- Jura JB, Dillard TA. Complete resection of endobronchial hamartoma by electrocautery and argon plasma ablation via fiberoptic bronchoscopy. *Chest* 2003; 124 (supplement) 4: 289-90.