

CAS CLINIQUE / CASE REPORT

SPONTANEOUS LATERAL ABDOMINAL WALL HEMATOMA COMPLICATING CHRONIC OBSTRUCTIVE PULMONARY DISEASE EXACERBATION

<http://www.lebanesemedicaljournal.org/articles/59-3/case1.pdf>

Fadi I. JABR¹, Nedaa SKEIK²

Jabr FI, Skeik N. Spontaneous lateral abdominal hematoma complicating chronic obstructive pulmonary disease exacerbation. *J Med Liban* 2011 ; 59 (3) : 160-161.

ABSTRACT : Lateral abdominal wall hematoma is a rare and potentially life-threatening condition. We report a case of a spontaneous lateral abdominal wall hematoma that developed in a patient with severe cough caused by chronic obstructive pulmonary disease (COPD) exacerbation. The hematoma resolved with conservative management.

INTRODUCTION

According to their location, abdominal wall hematomas can be divided into two types: rectus sheath hematoma and lateral abdominal wall hematoma. More commonly observed, rectus sheath hematoma is usually caused by epigastric vessel tear (inferior or superficial epigastric artery) and is often associated with anticoagulation [1]. Lateral wall hematoma is a rare condition with only few cases reported in the literature.

We report a case of spontaneous lateral abdominal wall hematoma caused by severe cough in a patient with chronic obstructive pulmonary disease (COPD).

CASE REPORT

A 37-year-old man with a history of COPD and tobacco abuse, presented with a sudden onset of right lateral abdominal wall pain and swelling starting four days after an episode of severe productive cough and sneezing. He did not complain of fever, chills, diarrhea or rectal bleeding and he denied any history of trauma, coagulopathy or anticoagulant therapy.

Physical exam revealed right-sided abdominal wall induration with tenderness. Initial hemoglobin and hematocrit were 15.9 g/dl and 44.8% respectively. Prothrombin time and activated partial thromboplastin time were normal. Computed tomography showed right lateral abdominal wall muscle edema and thickening suggesting lateral abdominal wall hematoma (Figure 1). Patient was managed conservatively with intravenous fluids, antitussives,

¹Hospital Medicine, Horizon Medical Center, Dickson, TN 37055, USA; ²Vascular Medicine, Mayo Clinic, Rochester, MN 55905, USA.

Correspondence: Fadi I. Jabr, MD. Department of Hospital Medicine. Horizon Medical Center. Dickson TN 37055. USA. e-mail: fjabr@netzero.com

Jabr FI, Skeik N. Hématome spontané de la paroi abdominale latérale comme complication d'une maladie pulmonaire obstructive chronique exacerbée. *J Med Liban* 2011 ; 59 (3) : 160-161.

RÉSUMÉ : L'hématome de la paroi abdominale latérale est une pathologie rare et potentiellement mortelle. Nous avons observé un cas d'hématome spontané de la paroi abdominale latérale développé chez un patient souffrant d'une toux sévère causée par une aggravation d'une bronchopneumopathie chronique obstructive. L'hématome a été résorbé après un traitement conservateur.

bronchodilators, solumedrol, and pain medications. He remained clinically stable without any increase in the hematoma size. Repeated hemoglobin level on the second and third day after the initial presentation was 15.2 and 15.1 g/dl respectively. The patient was discharged in a stable condition and his hematoma resolved completely upon follow-up.

DISCUSSION

Lateral abdominal wall hematoma is a rare condition usually caused by a rupture of the deep or superficial circumflex iliac arteries [2-5]. It can occur after a blunt trauma or an iatrogenic injury to the abdominal vessels.

Iatrogenic lesions have been reported during trocar placement for laparoscopic surgery [6] and during carotid artery stenting [4]. Spontaneous hemorrhage from the deep

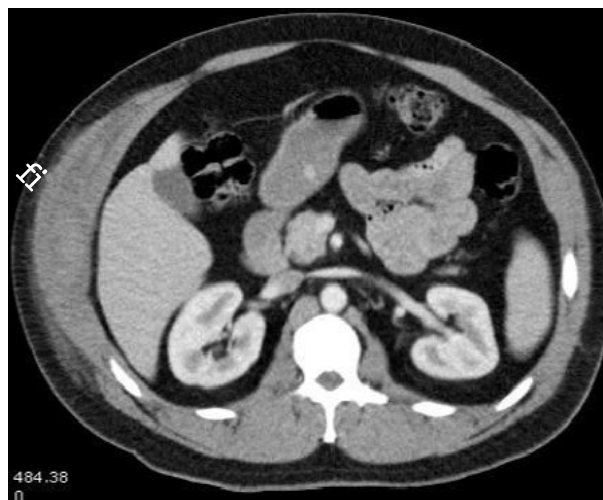


FIGURE 1

CT of abdomen showing right lateral wall hematoma (arrow).

circumflex artery or from ruptured femoral pseudoaneurysm has been also reported [2, 5, 7].

Predisposing factors include over-contraction of the abdominal muscles during coughing, sneezing or vomiting, weakness of the vessel wall secondary to arteriosclerosis, hypertension, advanced age, pregnancy, and obesity. Increased bleeding secondary to use of anticoagulants must be also a predisposing factor [1-2, 4]. Spontaneous lateral abdominal wall hematoma had been rarely described in the literature as a complication of status asthmaticus and acute COPD exacerbation [8].

Due to its rarity, abdominal wall hematoma can be mistaken for acute appendicitis, incarcerated inguinal hernia, acute cholecystitis, ovarian torsion, and even acute aortic dissection. Diagnosis can be clinically suspected, but ultrasound or computed tomography can help in excluding other differential diagnosis and in reducing unnecessary surgery. For most patients, treatment can be conservative and includes bed rest and analgesics [1, 4]. Follow-up imaging studies are recommended if observation only has been selected.

Transcatheter arterial embolization with Gelfoam and microcoils is effective and less invasive than surgery in controlling active bleeding [4-5, 9]. Surgery is restricted for life-threatening cases with rupture into the free peritoneum, infection, or expanding hematoma.

In conclusion, lateral abdominal wall hematoma is a rare but life-threatening condition and it should be considered in the differential diagnoses of sudden or subacute onset abdominal pain. If suspicion is high, imaging modalities of the abdomen is recommended.

CONFLICTS OF INTEREST

No financial support was needed or provided by any source.

REFERENCES

1. Jabr FI. Rectal sheath hematoma in an elderly woman after anticoagulation treatment. *J Am Geriatr Soc* 2006 ; 54 : 871-2.
2. Shimizu T, Hanasawa K , Yoshioka T et al. Spontaneous hematoma of the lateral abdominal wall caused by a rupture of a deep circumflex artery : Report of two cases. *Surg Today* 2003 ; 33 : 475-8.
3. Lefere P, Gryspeerdt S, Van Holsbeek B, Baekelandt M. Diagnosis and treatment of expanding hematoma of the lateral abdominal wall after blunt abdominal trauma. *Eur Radiol* 1999 ; 9 : 1553-5.
4. Fukunaga N, Ikeyama S, Satomi J, Satoh K. Lateral abdominal wall hematoma as a rare complication after carotid artery stenting : a case report. *World Journal of Emergency Surgery* 2009 ; 4 : 39.
5. Katsumori T, Nakajima K. A case of spontaneous hemorrhage of the abdominal wall caused by a rupture of a deep iliac circumflex artery treated by a transcatheter arterial embolization. *Eur Radiol* 1998 ; 8 : 550-2.
6. Blazer KM, Witte H, Recknagel S, Koziarka J, Waleczek H. Anatomic guidelines for the prevention of abdominal wall hematoma induced by trocar placement. *Surg Radiol Anat* 1999 ; 21 : 87-9.
7. Ma M, Snook CP. Ruptured femoral pseudoaneurysm presenting as a lateral abdominal wall hematoma. *J Emerg Med* 2005 ; 29 : 147-50.
8. Karem M, Şahin TT, Bedirli A, Azili C, Tezcaner T. Spontaneous lateral abdominal wall hematoma as a complication of status asthmaticus. *Akademik Acil Tip Dergisi* 2006 ; 4 : 15-16.
9. Nakayama T, Ishibashi T, Eguchi D et al. Spontaneous internal oblique hematoma successfully treated by transcatheter arterial embolization. *Radiat Med* 2008 ; 26 : 446-9.